

---

# Minimally Invasive Versus Open TLIF in the Management of Lumbar Spondylolisthesis

Ahmed Nagaty<sup>1,\*</sup>, Ashraf Yassin Amer<sup>3</sup>, Ahmed Gamil Hassan<sup>3</sup>, Ahmed Samir Rady<sup>3</sup>, Hatem Sabry<sup>1,2</sup>

<sup>1</sup>Department of Neurosurgery, Ain shams University, Cairo, Egypt

<sup>2</sup>Department of Neurosurgery, Saudi German Hospital, Cairo, Egypt

<sup>3</sup>Department of Orthopedics, Saudi German Hospital, Cairo, Egypt

## Email address:

Ahmednagaty@med.asu.edu.eg (A. Nagaty), dr.ashrafyassin@gmail.com (A. Y. Amer), dr.ahmedgamil@hotmail.com (A. G. Hassan), dr.ahmedrady@gmail.com (A. S. Rady), sabrymd@gmail.com (H. Sabry)

\*Corresponding author

## To cite this article:

Ahmed Nagaty, Ashraf Yassin Amer, Ahmed Gamil Hassan, Ahmed Samir Rady, Hatem Sabry. Minimally Invasive Versus Open TLIF in the Management of Lumbar Spondylolisthesis. *International Journal of Neurosurgery*. Vol. 4, No. 2, 2020, pp. 50-58.

doi: 10.11648/j.ijn.20200402.16

**Received:** August 29, 2020; **Accepted:** September 28, 2020; **Published:** October 7, 2020

---

**Abstract:** This study aims to assess the difference between minimal invasive TLIF surgery and conventional TLIF surgery in cases of lytic spondylolisthesis, as regards pain, disability, hospital stay and complications. Lytic Spondylolisthesis patients may require fusion of one or more spinal segments to treat their condition adequately. The chances of achieving a successful lumbar spinal fusion has increased. TLIF technique is gradually being accepted in these cases and widely used by most spine surgeons. Minimal invasive TLIF is a recent trend for spinal fusion. This is a prospective randomized comparative study conducted from March 2016 to December 2018 included forty patients with low grade lytic spondylolisthesis that underwent surgeries. Twenty patients underwent MI-TLIF through percutaneous posterior lumbar pedicular screw fixation, microscopic minimally invasive transformational discectomy and interbody cage fusion (patients group "A") and another twenty patients underwent traditional open posterior lumbar pedicular screw fixation and TLIF (control group "B"). In our results, both surgical techniques showed improvement in pain and function within 12 months (follow up period), but group A showed statistically significant improvement in pain and function in the 1<sup>st</sup> three months. Regarding blood loss, need for transfusion and hospital stay, group A showed statistically significant better results. As a conclusion, minimally invasive TLIF is a better option in surgical management of spondylolisthesis especially in the early postoperative period.

**Keywords:** Spinal Fusion, Spondylolisthesis, Minimal Invasive Spine Surgery, TLIF

---

## 1. Introduction

Spinal fusion in the properly selected patient has been well demonstrated to be effective in improving pain, function, and quality of life. However, many patients resist having a surgical fusion due to concerns over the morbidity of the procedure [1]. Some patients require fusion of one or more spinal segments to treat their condition adequately. The chances of successful lumbar spinal fusion are increased significantly by the addition of a rigid fixation device [2].

In 1982, Harms and Rolinger described the transforaminal lumbar interbody fusion (TLIF) technique to create a 360-

degree fusion via a single posterolateral approach [3]. In the TLIF procedure, bone graft and an interbody spacer are placed via a posterolateral transforaminal route into a distracted disc space in conjunction with a supplemental pedicle screw construct [4].

Numerous minimally invasive approaches to the lumbar spine have been developed to minimize approach-related morbidity. Recently, systems for percutaneous pedicle screw and rod insertion under fluoroscopic control or image guidance have become available [5]. Concurrently, surgical instruments, tools for disc space preparation, segmental distraction, and reposition, as well as modified interbody

cage systems, have been engineered specifically for use in percutaneous fusion procedures. [6]

Over the past decade, minimally invasive transforaminal lumbar interbody fusion (MI-TLIF) has become exceedingly popular for treating a variety of lumbar spinal disorders.; The use of tubular dilators for decompression in concert with specialized interbody cages and percutaneous screws has led to viable minimally invasive alternatives to open fusion surgery. [1]

Minimally invasive TLIF (MI-TLIF) was introduced to minimize iatrogenic soft tissue and muscle injury associated with traditional open TLIF while maintaining comparable clinical, radiological, and economic outcomes.

## 2. Patients and Methods

This is a prospective randomized comparative study included forty patients underwent surgeries from March 2016 to December 2018.

Twenty patients underwent MI-TLIF through percutaneous posterior lumbar pedicular screw fixation, microscopic minimally invasive transforaminal discectomy and interbody cage fusion (as patients group, Group A) and another twenty patients underwent traditional open posterior lumbar pedicular screw fixation and TLIF (as control group, Group B). These two group were compared as regards low back pain and limb pain (Visual Analogue Score “VAS”), disability according to “Oswestry Disability Index – ODI”, hospital stay and peri-operative complications.

### 1) Inclusion criteria:

- a) Lytic type spondylolisthesis: grade I and II.
- b) Single level affection.
- c) Patient age between 20 to 45 years.
- d) Patients complaining of low back pain and or unilateral sciatica.
- e) Failed conservative treatment for 3 months.

### 2) Exclusion criteria:

- a) Grade III and IV spondylolisthesis.
- b) Multiple levels affection.
- c) Previous back surgery.
- d) Patients complaining of bilateral sciatica.
- e) Morbid obesity.
- f) L5-S1 spondylolisthesis with high iliac crest (at the level of L4 pedicles on AP lumbosacral X-ray).
- g) Major concurrent medical illness (e.g., patients in current major psychiatric illness, osteoporosis, and general contraindications for anesthesia).

## 3. Operative Procedures

### 3.1. Minimally Invasive TLIF Approach (MI-TLIF): (Group A)

#### 3.1.1. Pre-operative Planning and Set Up

Preoperative planning can be useful in determining the proper starting point and screw trajectory. A CT axial view or x-ray AP view demonstrates the distance lateral to the pedicle

initially taken through the skin. The starting point is rarely directly over the pedicle.

#### 3.1.2. Patient Positioning

The patient should be positioned prone supported on rubber foam blocks. A radiolucent frame with bedrail is used. We made sure that adequate fluoroscopic images of the pedicles can be obtained in both an AP and lateral views before proceeding. The patient is then prepared and draped in the usual fashion. A longer prepared area is also necessary because the rod inserter can have an entry point relatively far away from the levels being instrumented. Fluoroscopy in the anterior-posterior and lateral views is used to locate the affected level.

#### 3.1.3. Minimally Invasive Transforaminal Interbody Cage Application

*Incision location and tube trajectory:* The location of the incision is approximately 4 cm laterally off midline; an incision mark is made on the skin at the level of the affected disc space. A K-wire is inserted at this point, aiming for identifiable bony landmarks such as the inferior edge of the lamina and facet joints. After fluoroscopic verification of placement, a 2 cm longitudinal incision is made. Penetrating the fascia to easily accommodate the dilators. Successively increasing dilating tubes are inserted under intermittent fluoroscopy followed by retractor insertion.

The retractor can then be opened for a customizable exposure by expanding the blades as necessary. Position of the independent blade either medially or laterally and angling of the retractor allows for preferential instrument maneuverability and reaches in these directions for thorough disc removal and optimal implant insertion.

In performing the TLIF, we approach just lateral to the laminar edge and remove the entire facet on one side in order to safely insert the inter-body device without significant nerve root and thecal sac retraction. The operative corridor exposes the thecal sac and exiting nerve root medially and the bony landmarks of the laminectomy cranially and caudally as well as the pedicles. Under direct visualization and with minimal retraction of the nerve root, the interbody disc can be identified and removed, and the end plates prepared for the interbody graft.

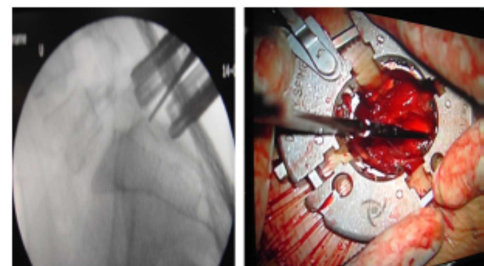


Figure 1. A minimal invasive retractor.

#### 3.1.4. Percutaneous Pedicular Screws Insertion

##### a) Positioning of Skin Incisions

A 22-gauge spinal needle is used to verify the appropriate

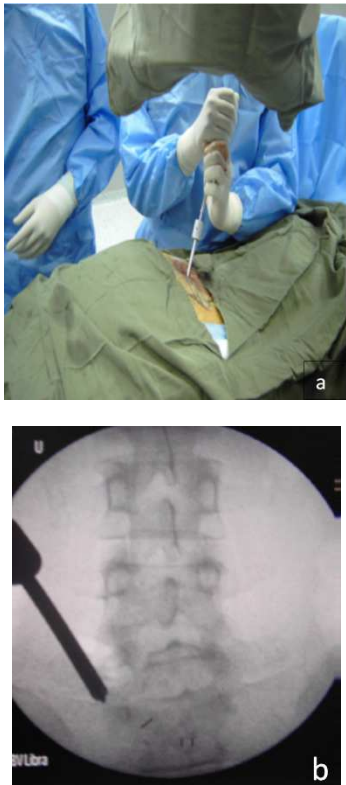
location of the skin incisions. The needle is positioned on the skin directly over the pedicle on an AP image. The needle is then moved laterally 1 to 2 cm and inserted through the skin to the intersection of the facet and transverse process.

#### b) Accessing the Pedicle

A pedicle access needle is used to gain access to the pedicle. After placing the pedicle access needle at the intersection of the facet and the transverse process, the needle may be advanced partially through the pedicle.

#### c) Guide Wire and Dilators Insertion

The inner stylet of the needle is removed to allow the guide wire to be inserted into the pedicle carefully as unintentional advancement potentially be dangerous. Once the guide wire is inserted, the needle may be removed. The fascia and muscle must be dilated to allow for screw placement. Three dilators are used to gently make a path of the appropriate dimensions. The first two dilators are removed, leaving the third dilator to serve as a tissue protection sleeve during the taping step.



**Figure 2.** (a and b). Needle Insertion. An A-P image should show the needle tip at the lateral margin of the pedicle initially. As the needle advances towards the base of the pedicle, on the lateral image, it should approach the pedicle center on the A-P image.

#### d) Pedicle Preparation and Screw Placement

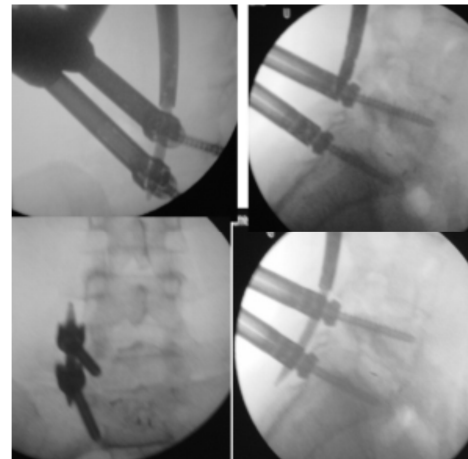
The pedicle is prepared by placing the tap over the guide wire and through the third dilation sleeve. Fluoroscopy should be used to verify the position of the guide wire and the tap during this step. The screw assembly is inserted over the guide wire and into the pedicle. After driving the screw assembly into the pedicle the guide wire is removed. The process is repeated for the second screw on the same side.

#### e) Connect the Extenders

Rotate the extenders so the two flat sides are facing each other. The male and female parts are then mated together and rotated so there is no gap between the two extenders. Once the extenders are connected and the flat surfaces are completely flush; the rod inserter can be attached.

#### f) Rod Insertion

The rod inserter is attached to the two screw assemblies by lining up the pegs of the inserter and the grooves of the assemblies. A rod is then placed into the tip of the rod inserter. After the rod is in place. A small skin incision is required, and then the rod is advanced through the muscle screw saddles as confirmed on lateral fluoroscopy.



**Figure 3.** Radiographic rod insertion.

#### h) Final Tightening & Assembly Removal

After verifying with A-P, lateral, and oblique views that the rod is seated in the heads of both screws, the set screws can be tightened. The rod inserter is then detached from the rod by reversing the steps of attachment. After followed by removal of the screw assembly. The final construct can then be viewed with A-P and lateral fluoroscopy.

### 3.2. Transforaminal Lumbar Interbody Fusion (TLIF): (Group B)

#### 3.2.1. Patient Positioning

The patient is positioned as mentioned in minimally invasive method.

#### 3.2.2. Surgical Exposure

The landmarks for the posterior approach are: spinous processes, posterior superior iliac spine and iliac wings yet an image intensifier is necessary in every case.

#### 3.2.3. Surgical Dissection

After the incision of the skin in the midline above the spinous processes and the dissection of the subcutaneous layers, the thoracolumbar fascia is incised with a cautery knife. The paraspinal musculature is sub-periosteally detached from the spinous process and the laminae. Care must be taken not to injure upper facet joint capsules.

**3.2.4. Lumbar Spine Pedicle Screw Insertion**

The pedicle entrance point is at the lateral border of the base of the superior articular process (mid transverse process point). The screw trajectory is angled 20°–25° to the midline. In the sagittal plane the screws take a course parallel to the upper vertebral endplates.

**3.2.5. Sacral Screw Insertion**

Screw placement in the first sacral pedicle located just below the L5/S1 facet angled medially 20° cranially toward the anterior corner of sacral promontory.

**3.2.6. Cage Application**

Pars interarticularis osteotomy with excision of the fibro-cartilaginous tissue of spondylolysis with excision of ligamentum flavum, cranial retraction of exiting root, discectomy and refreshing of cancellous bone of vertebral body by curetting the bony end plate then cage filled with bone graft (autogenous with or without synthetic graft) is applied.

**3.2.7. Wound Closure**

The thoracolumbar fascia needs to be closed over suction drains. The fascia needs to be sutured tightly by running sutures. Subcutaneous closure followed by skin closure by subcuticular absorbable sutures.

**4. Results**

This is a comparative study including 40 patients. 20 patients that underwent MI-TLIF (group A) and another 20 patients that underwent open conventional TLIF (group B). Early postoperative results data were obtained before hospital discharge, while late postoperative results data were obtained during follow up starting from 1<sup>st</sup> to 12<sup>th</sup> month. Follow up duration ranged from 12 to 29 months (average was 18 months).

*Baseline characteristics of patients:*

1-Age: Group A ranged between 21 and 35 years mean 29.1 years. Group B ranged between 22 and 44 years of age mean 30.5years.

*Table 1. Age distribution.*

Groups	Age		T-test	
	Range	Mean±SD	T	p-value
A	21 – 35	29.1±4.56	-0.74	0.464
B	22 – 44	30.5±7.49		

2-Sex: There was 18 male, 2 females in group A and no females in group B

3- Level: L5-S1 is the most common level encountered in the study, total of 28 cases 14 in Group A and 14 in Group B. L4-5 level was of 12 cases 6 in group A and 6 in group B. there was no other levels encountered in the study.

*Table 2. Levels included in both groups.*

Level		Groups		
		A	B	Total
L5-S1	N	14	14	28
	%	70	70	70

Level		Groups		
		A	B	Total
L4-5	N	6	6	12
	%	30	30	30
Total	N	20	20	40
	%	100	100	100
Chi-square	X2	1		
	p-value	0		

4- Spondylolisthesis Grades: In group A there were 16 cases grade I and 4 cases grade II. In group B grade I were 12 cases and grade II were 8 cases.

*Table 3. Different grades of spondylolisthesis in both groups.*

Grade		Groups		
		A	B	Total
Grade I	N	16	12	28
	%	80	60	70
Grade II	N	4	8	12
	%	20	40	30
Total	N	20	20	40
	%	100	100	100
Chi-square	X2	1.33		
	p-value	0.248		

5- Surgery Time: Group A ranged between 160-240 minutes, mean was 190.5 minutes. Group B ranged between 120-210 minutes and mean was 153.5 minutes. Group A showed statistically significant longer surgery time than group B.

*Table 4. Surgical duration statistics.*

Groups	Surgery time (minutes)		T-test	
	Range	Mean±SD	T	p-value
Group A	160 – 240	190.5±25.5	4.93	<0.001*
Group B	120 – 210	153±21.8		

“\*” Clinically significant value.

6- Blood Loss: In Group A, blood loss was ranged between 110-300cc (mean 168cc) and in Group B, it was ranged between 250-840cc (mean 476.5 cc). Group A showed statistically significant less mean blood loss than group B.

7- Need for Transfusion: Lower number of cases needed transfusion in Group A (one out of 20) than in Group B (two out of 20) and was statistically non-significant.

8- Hospital Stay: In Group A, hospital stay ranged between 2 to 5 days with mean of 2.88 days. In Group B, it ranged between 2 to 16 days with mean of 5.12 days. There is statistically significant longer duration of stay in group B than in group A.

*Table 5. Hospital stay statistics.*

Groups	Hospital stay (days)		T-test	
	Range	Mean±SD	T	p-value
Group A	2 – 5	2.9±1.3	-1.95	0.046*
Group B	2 – 16	5.1±4.4		

“\*” Clinically significant value.

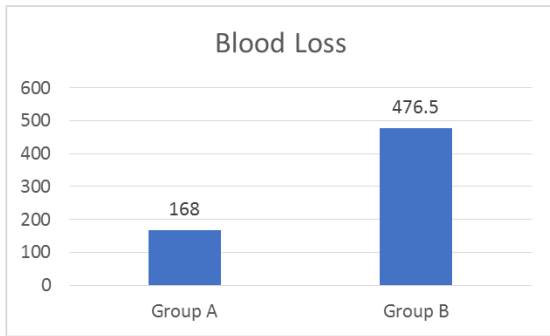


Figure 4. Mean blood loss.

9- Infection: There was only one case of deep infection (in Group B), representing 5% of the control cases. And 6 cases of superficial infection, 4 in Group B representing 20% of the open TLIF cases and 2 cases were recorded in the minimally invasive group representing 10%.

All were treated conservatively by antibiotic except one patient in A group had secondary sutures under local anesthesia. It was statistically non-significant.

10- There was no CSF leak, dural tears, screws malpositioning, loosening of screws or rapidly progressive adjacent segment disease in any of the cases of the study during surgery or later in the follow-up period (for 1 year).

11- Cage Extrusion and Redo Surgery: There was a case of posterolateral cage extrusion in Group B, failed conservative treatment for 6 months (patient initially declined redo) and necessitated redo surgery for repositioning of cage.

There were no other complications in both groups that might necessitate redo surgery encountered in both groups in first year of follow-up and this was statistically insignificant.

12- Oswestry Disability Index:

Table 6. ODI statistics.

ODI	Group A	Group B	T-test	
	Mean±SD	Mean±SD	T	p-value
Preoperative	20.3±8.1	20.53±8.9	-0.08	0.935
After 1m	21.78±7.8	24.13±10.8	-0.63	0.535
After m	10.56±5.1	14.833±9.3	-1.43	0.166
After 6m	6±5.6	9.000±9.4	-0.75	0.470
After 12m	5±4.4	8.250±7.7	-1.26	0.219

In Group A mean preoperative ODI was 20.3, although it showed mild increase in the 1 month patient evaluation, yet it decreased significantly in further follow-ups starting from 3rd month until reaching 5.0 in 12 months follow-up evaluation. This can be compared to group B mean preoperative ODI which was 20.53 and showed a similar

curve, increasing value in the first month post-operative evaluation, yet also decreasing thereafter in further follow-up until the 12<sup>th</sup> months evaluation.

Statistically significant different results were only obtained in 6<sup>th</sup> and 12<sup>th</sup> months evaluations, proving better outcome for group A patients regarding the ODI.

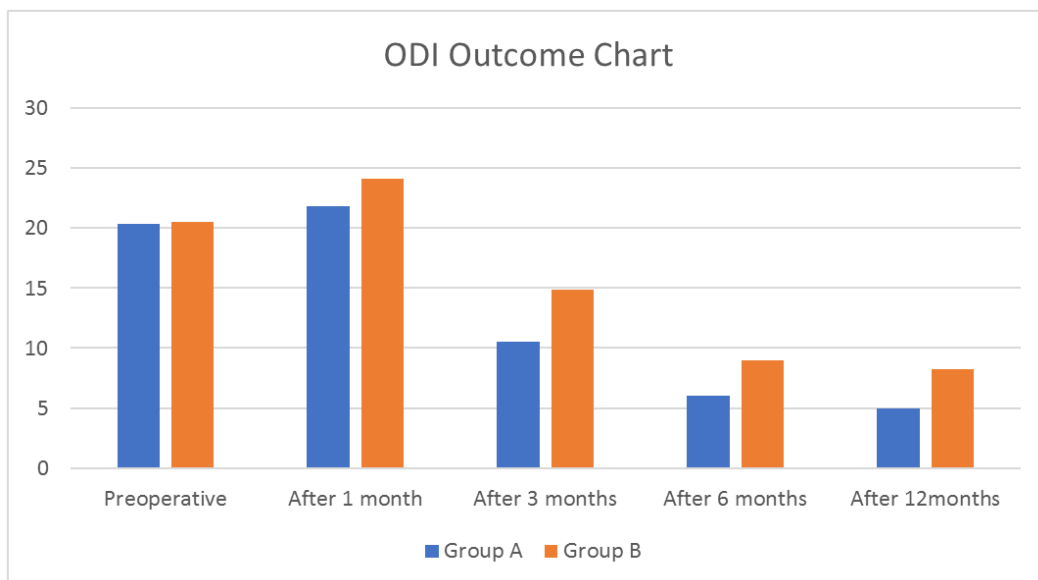


Figure 5. ODI outcome comparing Groups A and B.

13- VAS Back: Preoperative VAS score for low back pain in group A started at a mean of 7.3 and showed statistically significant decrease of values starting of immediate postoperative period reaching a 2.3 value at the 12<sup>th</sup> month

follow-up evaluation.

On the contrary to group A, group B curve started to show statistically significant decrease of VAS for low back pain starting from 3<sup>rd</sup> month follow-up evaluation.



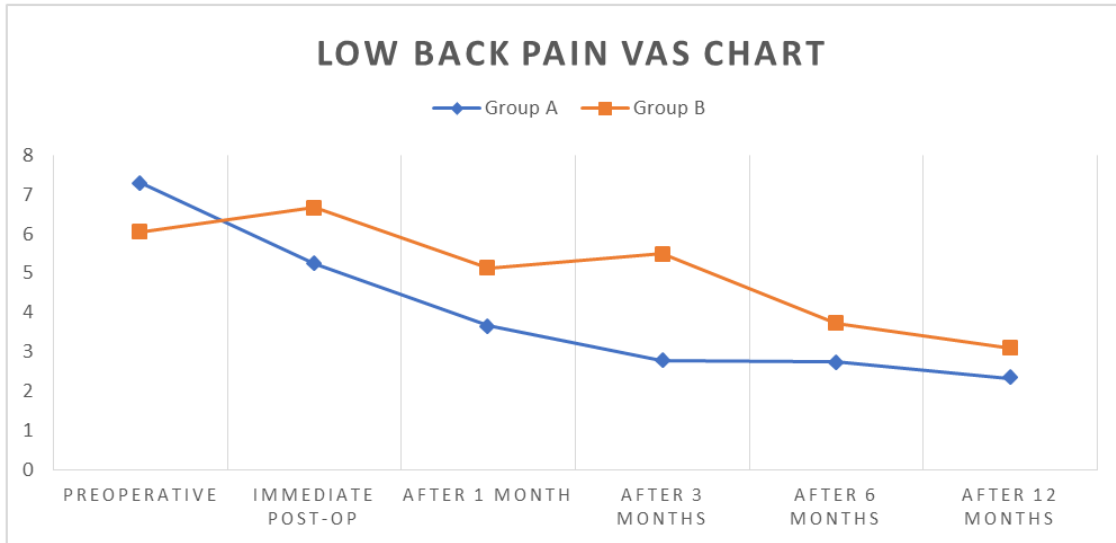


Figure 6. Low back pain VAS, comparing groups A and B.

Table 7. Low back pain VAS statistics.

VAS Back	Group A	Group B	T-test	
	Mean±SD	Mean±SD	T	p-value
Preoperative	7.3±1.3	6.06±2.2	2.074	0.045*
Early Post	5.25±2.6	6.67±2.9	-1.109	0.280
After 1m	3.67±2.5	5.13±2.4	-1.407	0.172
After 3m	2.78±1.8	5.5±1.6	-3.270	0.004*
After 6m	2.75±1.2	3.71±1.6	-1.345	0.201
After 12m	2.33±1.4	3.08±2.5	-0.891	0.383

“\*” Clinically significant value.

14- VAS limb: The mean for group A preoperative VAS score of limb pain was 5.7 with statistically significant decrease of values starting from the immediate postoperative period, reaching 2.2 at the 12<sup>th</sup> month follow-up evaluation.

On the contrary group B curve starting to show statistically significant decrease only starting from the 6<sup>th</sup> month follow-up (preoperative mean was 5.2 and 12<sup>th</sup> month postoperative mean was 2.3).

Table 8. Limb pain VAS statistics.

VAS Limb	Group A	Group B	T-test	
	Mean±SD	Mean±SD	T	P-value
Preoperative	5.7±1.6	5.24±2.2	0.751	0.458
Early Post	2.6±2.8	5.33±3.4	-1.811	0.085
After 1m	2±2.1	4.25±3.1	-2.094	0.047*
After 3m	1.89±1.8	4±3.3	-2.023	0.055
After 6m	1.75±2.29	2.57±2.8	-0.643	0.531
After 12m	2.17±2.5	2.33±2.7	-0.156	0.877

“\*” Clinically significant value.

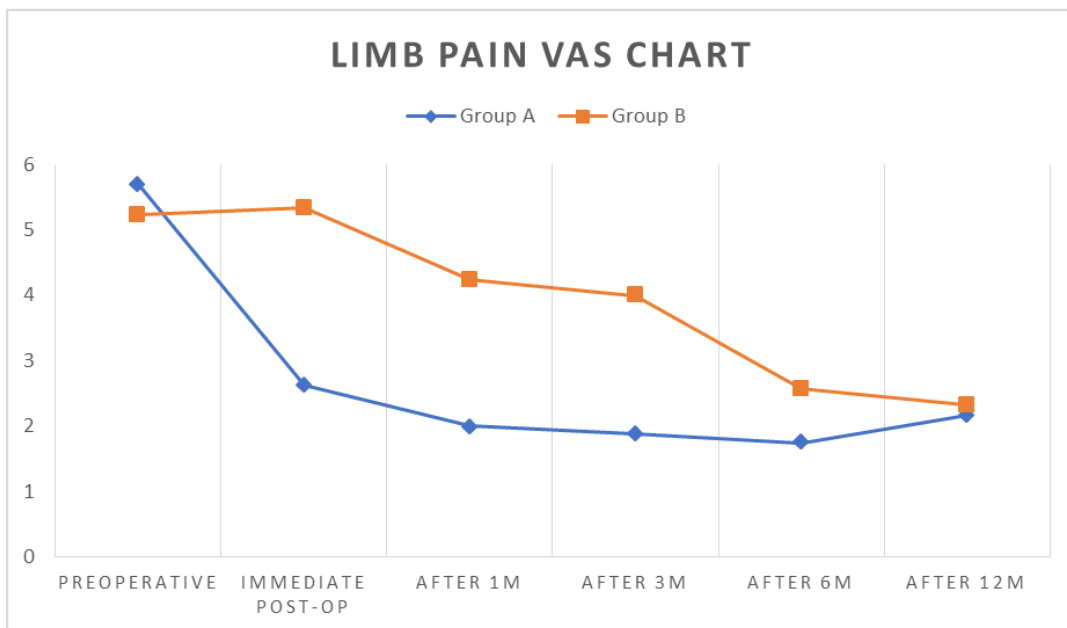


Figure 7. Limb pain VAS, comparing groups A and B.

## 5. Discussion

TLIF technique is gradually being accepted and widely used by clinicians. But the conventional open TLIF has been criticized for iatrogenic damage due to the extensive peeling of soft tissue and muscle [7]. In recent years, the surgical treatment of lumbar degenerative disease has showed the minimally invasive trend, and TLIF technique has developed to mini-open incision. Expandable passage tube minimally invasive system, such as Quadrant system, establishes the surgical channel using the step-by-step expansion method, exposing limitedly and minimizing the tissue damage in surgical approach and surgical procedures [8].

Since the introduction of MI-TLIF in the early 2000s by Foley et al. as an alternative to traditional TLIF, several studies have compared both techniques for perioperative, postoperative, clinical, and radiological outcomes. The parameters that have been compared most often between the two techniques are operative time, blood loss, LOS, complication rate, radiation exposure time, and various pain scores. Other items include fusion rates, clinical and radiological outcomes, and the costs involved in both procedures to evaluate the cost-effectiveness of the techniques. On the other hand, other parameters, such as operative time and complication rate, remain highly controversial when comparing MI-TLIF and traditional open TLIF [9].

Compared with the conventional open surgery, it can not only complete the operation, but also achieve the goal of smaller incision, better internal stability, less systemic and local responses, faster tissue healing, shorter functional recovery time and better psychological effect. Also, minimally invasive TLIF significantly reduces the risk of bleeding and surgical complications, postoperative serum CPK level is decreased, bedridden time is reduced, postoperative ODI and VAS scores are improved better, and the recovery cycle is shortened [10].

We aimed in this study to include cases with spondylolisthesis due to pars defect only grade one or two. All cases we included had low back pain and unilateral radicular symptoms; this is to do microscopic discectomy through unilateral facetectomy with insertion of TLIF interbody cage at the same site of radicular symptoms, percutaneous posterior pedicular screws we inserted bilaterally (same incision of microscopic TLIF on one side and two different incisions on opposite side).

It was well noticed that the results of the last cases are better than the first cases mainly regarding surgery duration and subsequently other parameters, this is normal if considered the learning curve and the factor that this procedure is completely new.

For open procedure, our study operative time (153, 5 min) was better than of Inamdar et al. (240 min) that compared posterior lumbar interbody fusion versus intertransverse fusion [11].

For MI-TLIF procedure; our study operative time results were longer than results found by Logroscino et al. [12]. (171

min), Kim M et al. [13] (150.7 min) and Foley et al. (155 minutes) [14].

According to Hammad et al. meta-analysis [9], twenty-seven studies had sufficient data regarding the operative time. The mean operative time was 214.69 min in the MI-TLIF group vs. 198.03 min in the Open TLIF group. Based on this meta-analysis, the difference was not significant ( $P = 0.78$ )

This is probably because they used virtual fluoroscopic guidance that eliminate time needed for A-P and lateral images. First few cases of MI-TLIF, screw application was time consuming but last few cases rod application was more time consuming probably due to regression of rod applicator targeting device quality.

In our study, blood loss was comparable to the results of Issacs et al. [15] reporting a mean of 140 cc, but was more than Logroscino et al. [12] reporting only 126 cc and was lower than the results of Kotani et al. [16] of 181 ml, taking into consideration that we inserted interbody cage and they did not.

In comparison to Hammad et al meta-analysis study, twenty-nine studies had sufficient data regarding the amount of blood loss. The mean blood loss volume was 247.82 ml in the MI-TLIF group vs. 568.18 ml in the Open TLIF group. The difference was highly significant ( $P < 0.00001$ ) [9].

In our study, hospital stay was comparable to Foley et al. [14], taking into consideration they used anterior approach for insertion of interbody cage (ALIF), but were better than Logroscino et al. [12] (5.3 days) and Kotani et al. [16] (3.4 days).

The immediate post-operative low back pain has increased in conventional surgery group rather than in MI-TLIF group, this is explained that part of this pain is due to extensive muscle cutting needed in open group in comparison to minimal muscle retraction and no mid line muscle separation in MI-TLIF group.

According to Hammad et al. [9], twenty-five studies had sufficient information on length of hospital stay (LOS). The mean LOS was 5.05 days in the MI-TLIF group vs. 6.92 days in the open TLIF group. The difference was highly significant ( $P < 0.00001$ )

Our results of immediate postoperative low back pain VAS are inferior to the results of Logroscino et al. (VAS = 2.1), but he did not divide VAS into back and radicular pain, and this may explain their better results [12].

There were statistically significant differences between two groups in immediate, one-month follow-up and three months follow-up. So both open and MI-TLIF procedure effectively reduce LBP on long follow up with no statistical difference, but MI-TLIF procedure is more effective in the mean change of reduction of LBP, this explained by absence of the muscle cutting factor in MI-TLIF procedure.

This is inferior to the result found by Kim et al. [13], their mean change of VAS scores for back pain was (4.5), the explanation for this is that they did not decompress the nerve root posteriorly, instead they only removed disc from anterior. As well as inferior to that of Inamdar et al. [11]

considering that this study had longer follow-up period and a greater number of cases.

Our results of mean reduction of LBP is lower than what Kotani *et al.* [16] (they did not use interbody cage) So we doubt the efficacy of interbody cage placement for fusion in reduction of low back pain in comparison to posterolateral on lay fusion.

Facetectomy and discectomy done in both open group and MI-TLIF group effectively reduce radicular pain, also the distraction obtained by interbody cage greatly increased foraminal height, so nerve root become free of compression. Both procedures had markedly improved radicular pain and MI-TLIF procedure was better in early change of the VAS for radicular pain than open technique.

Our results were not comparable to the result found by Kim *et al.* [13]. The mean change of VAS scores for leg pain was 4.4. On the contrary, they were comparable to those found by Logroscino *et al.* [12]. The MI-TLIF procedure is equally effective as conventional open technique in giving the patients the same advantage of improvement of functional score and recovery to relevant ordinary life activity in the late follow-ups and even better in early follow-ups.

Our functional scores were inferior to Inamdar *et al.* [11], considering that their preoperative functional score was better than our preoperative score (suspecting the study was biased and included cases with good preoperative functional score and excluded those with poor preoperative functional score), this could explain the difference between two results.

Our functional scores were comparable Logroscino *et al.* [12] and were better than Kotani *et al.* [16], taking into consideration that his preoperative functional score was lower than ours. This is an important issue about the efficacy of interbody fusion and whether it improves patient functional score, as it improves the fusion rate.

Our results regarding ODI Score also was comparable to Hammad *et al.* [9]. Twenty studies contained sufficient data on the Oswestry Disability Index (ODI) scores, expressed in percent. The mean preoperative ODI score was 43.08 in the MI-TLIF group vs. 42.95 in the Open TLIF group; the difference was not statistically significant. The mean ODI score at the final follow-up was 19.48 in the MI-TLIF group vs. 20.62 in the Open TLIF group, and the difference was not significant ( $p=0.25$ ).

There was no malpositioned screw in both groups due to the use of intraoperative imaging for confirmation in both open and MI-TLIF and experience in conventional open technique. Safety precautions regarding radiology exposure were applied. Our screws malpositioning results were superior to that of Raley [17] (9.7%), Smith *et al.* [18], Logroscino *et al.* [12] (1.25%) and Kim *et al.* [13] (11.1%).

The high rate of complication is interpreted in many studies to be due to learning curve, but we noticed that more than one system of percutaneous fixation was used, each with a different technique, and different learning curve.

The aim in follow up x-ray was to exclude loosening of screws and cage migration. there were no statistically significant differences between two groups in the

complication rate.

We had one of the early cases that suffered from postoperative radicular pain at the side of TLIF; the postoperative CT scan showed no misplacement of screws on this side nor cage malposition. We revised our technique in the next cases and minimized manipulations on the nerve root. This was the only encountered case in MI-TLIF group.

Two cases in open group with black lumbar discs in T2 MRI showed no improvement in VAS back pain probably due to inappropriate patient selection.

One case of open group showed malpositioned cage discovered 2 days postoperative as patient continued to complain from limb paresthesia. Patient was informed and advised to undergo repositioning surgery, but he refused and opted for conservative medical treatment which initially was helpful yet 3 months later he decided to undergo repositioning surgery, performed three months later and the paresthesia improved. (VAS was 8 reduced to 4) but pain did not disappear completely.

Infection was encountered in 7 patients all was treated medically except one in MI-TLIF group showed one of wounds dehiscence and necessitated secondary suturing, done under aseptic conditions under local anesthesia and patient was discharged one day afterwards with no further wound complications

Overall, our complication rates are superior to that of Logroscino *et al.* [12]; nonunion was observed in three patients (15%), without hardware mobilization and successful clinical outcome at last follow-up. One superficial wound infection resolved with antibiotic therapy.

Also, our results were superior to that of Kim *et al.* [13]; they encountered two cases of medial penetration of the pedicle border without neurological deficits and one case with a deep wound infection. However, there were no signs of neurological compromise or fusion failure at the final follow up.

Our results were comparable to that of Kotani *et al.* [16]; he found no major complications. However, two cases in the minimal invasive group demonstrated some surgical difficulty in rod passage during the percutaneous rod placement procedure. In these cases, the rods were placed directly on heads of pedicle screws via extended midline skin incisions involving lateral intramuscular exposure, but without conversion to a major open procedure. Both cases successfully led to solid bony fusion without implant failures.

## 6. Conclusion

MI-TLIF is an effective procedure in surgical management of low grades lytic spondylolisthesis.

In comparison to conventional TLIF, MI-TLIF has less blood loss, hospital stay, postoperative infection and need for transfusion. The MI-TLIF gives better reduction of low back pain, radicular pain in early follow-ups and functional recovery. Surgery duration of MI-TLIF cases is still statistically significantly longer than those of open conventional method but hopefully surgery duration will be



lesser with growing learning curve.

Intraoperative and postoperative complications other than infection showed similar rates. MI-TLIF requires more advances and a better equipped theater, hence, it is expensive surgery.

---

## References

- [1] Wang MY, Grossman J. Endoscopic minimally invasive transforaminal interbody fusion without general anesthesia: initial clinical experience with 1-year follow-up. *Neurosurg Focus*. 2016 Feb; 40 (2): E13.
- [2] Powers CJ, Isaacs RE. Minimally invasive fusion and fixation techniques. *Neurosurg Clin N Am*. 2006 Oct; 17 (4): 477–89.
- [3] Harms J, Rolinger H. [A one-stager procedure in operative treatment of spondylolistheses: dorsal traction-reposition and anterior fusion (author's transl)]. *Z Orthop Ihre Grenzgeb*. 1982 Jun; 120 (3): 343–7.
- [4] Mummaneni PV, Rodts GE. The mini-open transforaminal lumbar interbody fusion. *Neurosurgery*. 2005 Oct; 57 (4 Suppl): 256–61; discussion 256-261.
- [5] Foley KT, Gupta SK. Percutaneous pedicle screw fixation of the lumbar spine: preliminary clinical results. *J Neurosurg*. 2002 Jul; 97 (1 Suppl): 7–12.
- [6] Scheufler K-M, Dohmen H, Vougioukas VI. Percutaneous transforaminal lumbar interbody fusion for the treatment of degenerative lumbar instability. *Neurosurgery*. 2007 Apr; 60 (4 Suppl 2): 203–12; discussion 212-213.
- [7] Schwender JD, Holly LT, Rouben DP, Foley KT. Minimally invasive transforaminal lumbar interbody fusion (TLIF): technical feasibility and initial results. *J Spinal Disord Tech*. 2005 Feb; 18 Suppl: S1-6.
- [8] Li H-J, Ge D-W, Zhang S, Aisikeerbayi A-J, Wang H, He Y-L, et al. Comparative study between mini-open TLIF via Wiltse's approach and conventional open TLIF in lumbar degenerative diseases. *Eur Rev Med Pharmacol Sci*. 2018; 22 (1 Suppl): 53–62.
- [9] Hammad A, Wirries A, Ardeshiri A, Nikiforov O, Geiger F. Open versus minimally invasive TLIF: literature review and meta-analysis. *J Orthop Surg*. 2019 Jul 22; 14 (1): 229.
- [10] Brodano GB, Martikos K, Lolli F, Gasbarrini A, Cioni A, Bandiera S, et al. Transforaminal Lumbar Interbody Fusion in Degenerative Disk Disease and Spondylolisthesis Grade I: Minimally Invasive Versus Open Surgery. *J Spinal Disord Tech*. 2015 Dec; 28 (10): E559-564.
- [11] Inamdar DN, Alagappan M, Shyam L, Devadoss S, Devadoss A. Posterior lumbar interbody fusion versus intertransverse fusion in the treatment of lumbar spondylolisthesis. *J Orthop Surg Hong Kong*. 2006 Apr; 14 (1): 21–6.
- [12] Logroscino CA, Proietti L, Pola E, Scaramuzza L, Tamburrelli FC. A minimally invasive posterior lumbar interbody fusion for degenerative lumbar spine instabilities. *Eur Spine J Off Publ Eur Spine Soc Eur Spinal Deform Soc Eur Sect Cerv Spine Res Soc*. 2011 May; 20 Suppl 1: S41-45.
- [13] Kim M-C, Chung H-T, Cho J-L, Kim D-J, Chung N-S. Factors affecting the accurate placement of percutaneous pedicle screws during minimally invasive transforaminal lumbar interbody fusion. *Eur Spine J Off Publ Eur Spine Soc Eur Spinal Deform Soc Eur Sect Cerv Spine Res Soc*. 2011 Oct; 20 (10): 1635–43.
- [14] Foley KT, Gupta SK, Justis JR, Sherman MC. Percutaneous pedicle screw fixation of the lumbar spine. *Neurosurg Focus*. 2001 Apr 15; 10 (4): E10.
- [15] Isaacs RE, Podichetty VK, Santiago P, Sandhu FA, Spears J, Kelly K, et al. Minimally invasive microendoscopy-assisted transforaminal lumbar interbody fusion with instrumentation. *J Neurosurg Spine*. 2005 Aug; 3 (2): 98–105.
- [16] Kotani Y, Abumi K, Ito M, Sudo H, Abe Y, Minami A. Mid-term clinical results of minimally invasive decompression and posterolateral fusion with percutaneous pedicle screws versus conventional approach for degenerative spondylolisthesis with spinal stenosis. *Eur Spine J Off Publ Eur Spine Soc Eur Spinal Deform Soc Eur Sect Cerv Spine Res Soc*. 2012 Jun; 21 (6): 1171–7.
- [17] Raley DA, Mobbs RJ. Retrospective computed tomography scan analysis of percutaneously inserted pedicle screws for posterior transpedicular stabilization of the thoracic and lumbar spine: accuracy and complication rates. *Spine*. 2012 May 20; 37 (12): 1092–100.
- [18] Smith ZA, Sugimoto K, Lawton CD, Fessler RG. Incidence of lumbar spine pedicle breach after percutaneous screw fixation: a radiographic evaluation of 601 screws in 151 patients. *J Spinal Disord Tech*. 2014 Oct; 27 (7): 358–63.