

Case Report

Primary Central Nervous System Mucormycosis Mimicking Like a High Grade Glioma - A Rare Case Report

Basavaraj Tulajappa Badadal^{*}, Viraja Nimmagadda, Mallanna Mulimani, Mamatha Karigar, Savitri Nerune, Firos Khan

BLDE (Deemed to be University) Shri B M Patil Medical College and Research Centre, Vijayapur, Karnataka State, India

Email address:

btbnims2015@gmail.com (B. T. Badadal), viraja.nimmagadda@yahoo.com (V. Nimmagadda), mulimanims@gmail.com (M. Mulimani), mamath2007@gmail.com (M. Karigar), savitri.nerune@gmail.com (S. Nerune), firoskhan1505@gmail.com (F. Khan)

*Corresponding author

To cite this article:

Basavaraj Tulajappa Badadal, Viraja Nimmagadda, Mallanna Mulimani, Mamatha Karigar, Savitri Nerune, Firos Khan. Primary Central Nervous System Mucormycosis Mimicking Like a High Grade Glioma - A Rare Case Report. *International Journal of Neurosurgery*. Vol. 4, No. 2, 2020, pp. 59-62. doi: 10.11648/j.ijn.20200402.17

Received: August 29, 2020; **Accepted:** October 24, 2020; **Published:** November 23, 2020

Abstract: Mucormycosis is an invasive fungal infection caused by fungi of Mucoraceae family in immunocompromised individuals. CNS (Central Nervous System) Mucormycosis commonly arises from an adjacent para nasal sinus infection (Rhino cerebral), but isolated CNS Mucormycosis is a rare presentation as in our case. Presented as raised intra cranial pressure and no focal neurological deficit on evaluation found to have left temporal space occupying lesion with significant mass effect looking like high grade glioma. Operated on emergency basis, histopathology suggestive of invasive fungal infection managed accordingly. Results: As per literature primary CNS Mucormycosis has high mortality and morbidity even after best possible management. Our case was managed as per treatment protocol and after discharge patient got readmitted with surgical site infection and uncontrolled blood sugars and worsened medical condition, and finally died due to cardiac event after 28 days of diagnosis. Conclusion: Mucormycosis is an aggressive infection which can cause significant morbidity and mortality, thus needs high index of suspicion for early diagnosis and treatment.

Keywords: Central Nervous System Mucormycosis, Mucoraceae, Diabetic Ketoacidosis

1. Introduction

Mucormycosis is a fungal infection first described by Paulltauf in 1885, caused by the ubiquitous, filamentous, invasive fungi of Mucoraceae family in immunocompromised individuals and the most frequently isolated species is *Rhizopusoryzae*, *Rhizopusdelemar*, followed by less frequent *Rhizopusmicrosporus*, *Rhizomucorpusillus*, *Lichtheimia corymbifera* [1, 11, 12].

Central nervous system (CNS) Mucormycosis arises from an adjacent para nasal sinus infection (Rhino cerebral) by direct extension or hematogenous dissemination from the lungs, but isolated central nervous system Mucormycosis is a rare presentation. During an episode of fungemia, seeding may occur in brain tissue leading to this infection [2].

Diabetes mellitus, intravenous drug abuse, malignancy and

chronic immunosuppression are the major risk factors attributing to central nervous system Mucormycosis [3, 13]. Spore coat protein homologs (CotH2, Cot H3), existing in the germ rings of Mucorales, but absent in non-invasive fungi, were recognized as fungal ligands for Glucose-regulated protein 78 (GRP78), an endothelial cell receptor which is required for endocytosis and subsequent endothelial cell damage. GRP78's expression is enhanced by glucose; hence poor glycemic control is a risk factor for Mucormycosis. Homology modeling and docking studies pointed out structurally well-matched interactions between GRP78 and both CotH2 and CotH3 clarifying the specific vulnerability of diabetic ketoacidotic patients for this infection [4, 13]. Vast majority of the patients with isolated CNS Mucormycosis have involvement of the basal ganglia, present with lethargy and focal neurologic deficits and in isolated central nervous

system involvement, computed tomography usually shows poorly enhancing lesions and the cerebrospinal fluid cultures majority of the time yield negative results. Resection of the involved areas and biopsy help to diagnose. Even with aggressive medical and surgical intervention, the outcome is generally dismal [5].

2. Case Report

A 55 years old diabetic male presented with complaints of headache since 15 days, fever since 2 days. Headache was low grade, continuous, non radiating type and present throughout the day which was localized to left temporal region. Fever was of 2 days, intermittent type and reduced after taking medication. On examination, GCS (Glasgow Coma Scale): E3V5M6, vitals were within normal limits. Central nervous system examination was initially normal with no focal neurological deficits but later patient developed altered sensorium and became drowsy.

On investigation, Total WBC count: 15800 cells/mm, RBS: 284mg/dl, Creatinine: 0.6mg/dl, Sodium: 130mmol/l, Potassium: 4mmol/l, HbA1c: 14.8%, INR: 1.63, Urinary ketone bodies were present. Urine sugar: 1000mg/dl, HIV, HbsAg and HCV were negative. ECG was normal, Chest x-ray: Normal. Patient was started on insulin infusion to control sugars.

CT and MRI brain showed an ill defined non enhancing heterogeneous mass lesion with perilesional edema in the left temporal, parietal lobe producing significant mass effect with areas of blooming suggestive of bleed, necrosis and lookd like

high grade glioma. Then the patient was operated with left fronto temporo parietal craniotomy. Intraoperatively, dura was very tense. After durotomy there was liquefied brownish color brain matter in left temporal region with extensive thrombosis of cortical vessels, complete excision of necrotic tissue was done. Post operatively patient received injectable antibiotics, antifungal antiedema and other routine drugs. Patient was extubated with no significant neurological deficit post operatively.

Post operative CT (Computed Tomography) had showed edema at operated site, with complete excision of the lesion and very minimal bleed noted, patient was doing well shifted to step down ward, after for three days he was found to have decreased movements in right upper and lower limb and became drowsy. Repeat CT suggested left MCA (Middle Cerebral Artery) territory hypo density with increased edema which was managed conservatively.

Histopathology had showed large areas of necrosis with fungal elements which were broad, aseptate hyphae, branching at right angles suggestive of Mucormycosis. There were dense and diffuse inflammatory cell infiltrates comprised of lymphocytes, plasma cells, histiocytes around these fungal hyphae. These fungal filaments were seen in blood vessels suggestive angioinvasion. These features are suggestive of MUCORMYCOSIS and patient was started on injection Amphotericin B which was available antifungal with us, treated for seven days, mean time his sugars reached normal range, wound healed well and patient was discharged on 10th day with GCS E4V5M6 with improving right hemiparesis.

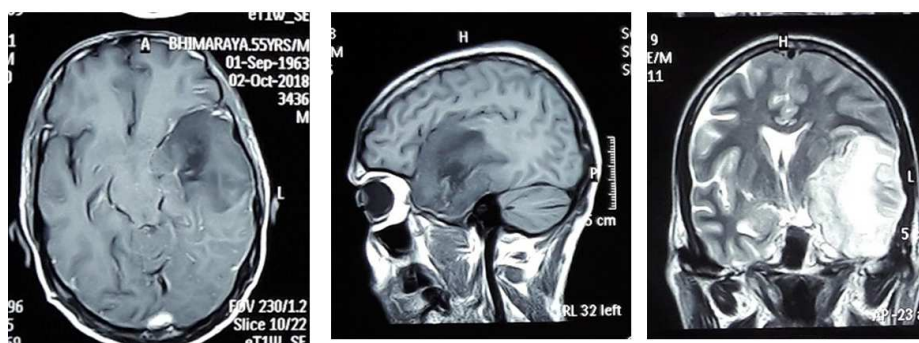


Figure 1. MRI (Magnetic Resonance Imaging) Brain Plain and contrast, showing left temporal T1-Iso to Hypo intense, T2 – Hyper intense, Contrast – Heterogeneously enhancing

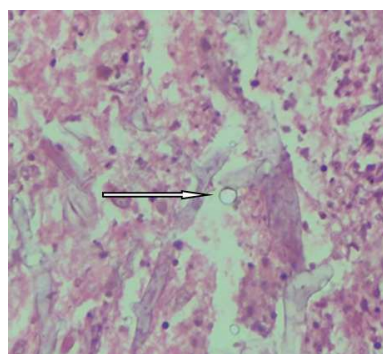


Figure 2. Microscopic picture showing prominent infarcts, angioinvasion and perineural invasion. (arrow showing branching pattern).

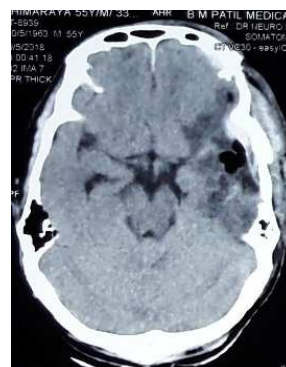

Figure 3. Post operative CT showing near total excision of the lesion with minimal perilesional edema.

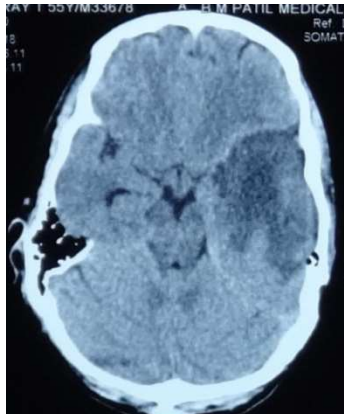

Figure 4. Repeat CT after three days showing edema increased along with MCA (Middle Cerebral Artery) territory infarct.

3. Discussion

Mucormycosis, after aspergillosis is the second most common invasive mold infection and poorly controlled diabetes mellitus is continuing to be the major risk factor of disease in developing countries. Where as in developed countries, malignancy remains as the major risk factor for Mucormycosis [6, 14]. In this case report, our patient had poor glycemic control with HbA1C 14.8% [13].

The most life threatening presentation of Mucormycosis which often dictates the functional outcome and survival of the patient, is the involvement of the central nervous system [7]. In a person with a history of intravenous drug abuse/injection, recent onset of altered sensorium (21%), headache (44%), hemiplegic/paresis (38%) [3] and dysarthria are the classic manifestations of intracranial Mucormycosis secondary to raised intracranial pressure, fever is also present in 50% of cases [8]. Our patient had headache, fever, recent onset altered mental status.

In intracranial Mucormycosis, computed tomography of the brain usually depicts unilateral basal ganglia hypo density and magnetic resonance images show unilateral basal ganglia mass lesions sometimes causing mass effect on surrounding structures, with diffusion restriction & hemorrhage attributed to angioinvasive nature of the fungus, varying degrees of contrast enhancement, and perilesional edema [9] but in our case, CT and MRI brain had shown an ill defined non enhancing heterogeneous mass lesion with perilesional edema in the left parietal temporal lobe with areas of blooming more in favor of malignancy. Surgical removal of the necrotic tissue and an aggressive antifungal treatment would help in this fatal condition [3]. Our patient was operated with left fronto temporo parietal craniotomy, with near total excision of mass. Intraoperatively, dura was very tense with liquefied brain matter in left temporal region with extensive thrombosis of cortical veins. Tissue was sent for histopathological study which revealed large areas of necrosis with fungal elements which were broad, aseptate hyphae, branching at right angles and invading blood vessels with dense and diffuse inflammatory cell infiltrates comprising of lymphocytes, plasma cells, histiocytes around these fungal hyphae and also

focal reactive gliosis which points to the definitive diagnosis of Mucormycosis.

According to a review done in 929 patients of Mucormycosis infection by Roden M. M. et al, the survival rates were 3% (8 of 241 patients) for untreated patients, 61% (324 of 532) for medically treated patients with antifungal, the drug of choice being Amphotericin B deoxycholate for Mucormycosis (antifungal therapy for Mucormycosis have to be continued until resolution of clinical signs and symptoms of infection and resolution of underlying immunosuppression) [1], 57% (51 of 90) for patients treated with surgery alone, and 70% (328 of 470) for patients treated with both antifungal and surgery [10]. Our patient was treated with both surgery and Amphotericin B. but due to financial constraints patient could not continue antifungal therapy, came after 20 days of discharge with wound infection and high blood sugar levels, with ketoacidosis and was managed conservatively but after 3 days patient had sudden cardiac arrest and could not be reviewed.

4. Conclusion

Mucormycosis is an aggressive infection which can cause significant morbidity and mortality, thus needs high index of suspicion for early diagnosis and treatment.

References

- [1] Brad Spellberg, Ashraf S. Ibrahim. Mucormycosis. In: Jameson J. Larry et al, editors. Harrison's Principles Of internal medicine. 20th ed. New York: McGraw-Hill Education; 2018. p. 1537-1541.
- [2] Malik AN, Bi WL, McCray B, Abedalthagafi M, Vaitkevicius H, Dunn IF. Isolated cerebral mucormycosis of the basal ganglia. *Clinical neurology and neurosurgery*. 2014 Sep; 124: 102.
- [3] Verma A, Brozman B, Petit CK. Isolated cerebral mucormycosis: report of a case and review of the literature. *Journal of the neurological sciences*. 2006 Jan 15; 240 (1-2): 65-9.
- [4] Gebremariam T, Liu M, Luo G, Bruno V, Phan QT, Waring AJ, Edwards JE, Filler SG, Yeaman MR, Ibrahim AS. CotH3 mediates fungal invasion of host cells during mucormycosis. *The Journal of clinical investigation*. 2014 Jan 2; 124 (1): 237-50.
- [5] Dhakar MB, Rayes M, Kupsy W, Tselis A, Norris G. A Cryptic Case: Isolated Cerebral Mucormycosis. *The American journal of medicine*. 2015 Dec 1; 128 (12): 1296-9.
- [6] Prakash, H.; Ghosh, A. K.; Rudramurthy, S. M.; Singh, P.; Xess, I.; Savio, J.; Pamidimukkala, U.; Jillwin, J.; Varma, S.; Das, A.; et al. A prospective multicenter study on mucormycosis in India: Epidemiology, diagnosis, and treatment. *Medical Mycology*. 2018, 57, 395–402.
- [7] Manesh, A.; Rupali, P.; Sullivan, M. O.; Mohanraj, P.; Rupa, V.; George, B.; Michael, J. S. Mucormycosis—A clinic epidemiological review of cases over 10 years. *Mycoses* 2019, 62, 391–398.

- [8] Kerezoudis, P.; Watts, C. R.; Bydon, M.; Dababneh, A. S.; Deyo, C. N.; Frye, J. M.; Kelley, P. C.; Kemp, A. M.; Palraj, B. V.; Pupillo, G. T. Diagnosis and Treatment of Isolated Cerebral Mucormycosis: Patient-Level Data Meta-Analysis and Mayo Clinic Experience. *World Neurosurgery*. 2019, 123, 425–434.
- [9] Hazama, A.; Galgano, M.; Fullmer, J.; Hall, W.; Chin, L. A. nity of Mucormycosis for Basal Ganglia in Intravenous Drug Users: Case Illustration and Review of Literature. *World Neurosurgery*. 2017, 98, 872. e1–872. e3.
- [10] Roden M. M., Zaoutis T. E., Buchanan W. L., Knudsen T. A., Sarkisova T. A., Schaufele R. L., Sein M., Sein T., Chiou C. C., Chu J. H., Kontoyiannis D. P. Epidemiology and outcome of zygomycosis: a review of 929 reported cases. *Clinical Infectious Diseases*. 2005; 41 (5): 634–653. (Matched ISSN: 1058-4838).
- [11] Arakkal G, Kasetty HK, Damarla S, Chintagunta S. Mucormycosis: A rare case report. *International Journal of Oral Health Sciences*. 2014 Jan 1; 4 (1): 46.
- [12] Oladeji SM, Amusa YB, Olabanji JK, Adisa AO. Rhino cerebral mucormycosis in a diabetic case report. *Journal of the West African College of Surgeons*. 2013 Jan; 3 (1): 93.
- [13] Cheema SA, Amin F. Five cases of rhino cerebral mucormycosis. *British Journal of Oral and Maxillofacial Surgery*. 2007 Mar 1; 45 (2): 161-2.
- [14] Guinea, J.; Escribano, P.; Vena, A.; Munoz, P.; Martinez-Jimenez, M. D. C.; Padilla, B.; Bouza, E. Increasing incidence of mucormycosis in a large Spanish hospital from 2007 to 2015: Epidemiology and microbiological characterization of the isolates. *PLoS ONE* 2017, 12, e0179136.