

## Case Report

# Supratentorial Hemangioblastomas Without Von - Hippel Lindau Disease – Case Report and Review

Jose Carlos Rodrigues Junior<sup>1,2,\*</sup>, Vithor Ely Bortholin da Silva<sup>1</sup>, Roberto Bezerra Vital<sup>2</sup>, Renan Luiz Lapate<sup>2</sup>, Marcelo Ferraz Campos<sup>1</sup>

<sup>1</sup>Department of Neurosurgery, Heliópolis Hospital, São Paulo, Brazil

<sup>2</sup>Department of Neurosurgery, Assunção Hospital, São Paulo, Brazil

### Email address:

josecarlosncr@gmail.com (J. C. R. Junior)

\*Corresponding author

### To cite this article:

Jose Carlos Rodrigues Junior, Vithor Ely Bortholin da Silva, Roberto Bezerra Vital, Renan Luiz Lapate, Marcelo Ferraz Campos.

Supratentorial Hemangioblastomas Without Von - Hippel Lindau Disease – Case Report and Review. *International Journal of Neurosurgery*.

Vol. 5, No. 1, 2021, pp. 1-3. doi: 10.11648/j.ijn.20210501.11

Received: April 27, 2020; Accepted: August 19, 2020; Published: January 4, 2021

---

**Abstract:** Background and Importance: Hemangioblastomas (HBL) are tumors constantly present in the neurosurgeon's daily life, affecting mainly the posterior fossa region. In patients with von Hippel-Lindau, their presence is even more striking. However, the authors, through a report of a case with the literature review, show that hemangioblastomas should also be part of the range of differential diagnoses of supratentorial lesions even in patients not carrying the genetic mutation. Clinical Presentation: A 45-year-old male patient has a 2 weeks history of headache associated with nausea and vertigo. In the last two weeks the pain was being progressively more frequently with increase in intensity and duration. At examination he was oriented, with face of pain, muscle examination was normal as all the neurological examination. The patient was submitted to a Magnetic Resonance (MR) of the brain that showed an expansive lesion in the brain located in the left frontal lobe, adjacent to the medial line with moderated adjacent edema and with gadolinium injection the tumor was heterogeneous almost solid with cystic parts and including adjacent impregnation of the dura of the midline. Surgical treatment was done. The lesion was completely resected including the dura of the convexity that was invaded by the tumor. Postoperative period was uneventful, with resolution of the headache and no deficits. Patient was discharged 3 days after surgery. Pathology reveals the lesion was a hemangioblastoma. Patient made genetic exams and confirms that didn't have Von Hippel Lindau disease. MR of the brain, almost 3 years of the surgery, reveals no tumor. Conclusion: Hemangioblastoma is a rare tumor, especially in its supratentorial location. However, this case reflects the importance of including HBL as a differential diagnostic allowing a better therapeutic planning, ensuring better prognosis and facilitating their treatment.

**Keywords:** Hemangioblastoma, Supratentorial, Von Hippel Lindau, Brain Tumor

---

## 1. Background and Importance

Hemangioblastomas are tumors constantly present in the neurosurgeon's daily life, affecting mainly the posterior fossa region. In patients with von Hippel-Lindau disease (VHLD), their presence is even more striking. However, the authors, through a report of a case with the literature review, show that hemangioblastomas should also be part of the range of differential diagnoses of supratentorial lesions even in patients not carrying the genetic mutation.

## 2. Clinical Presentation

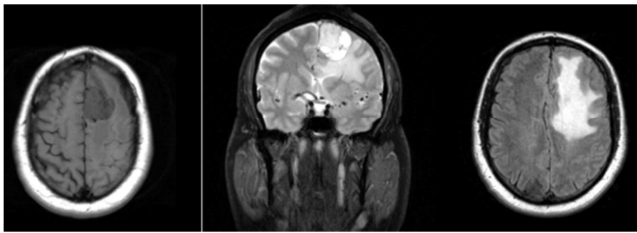
A 45-year-old male patient has a 2 weeks history of headache. His pain was localized in vertex area and was associated with nausea and vertigo. In the last two weeks the pain was being progressively more frequently, even daily in the last days, with increase in intensity and duration and not responding to common painkillers and non-steroid anti-inflammatory drugs.

He had testicle adenoma as teenager as his only previous disease. At examination he was oriented, with face of pain, muscle examination was normal as all the neurological exam.

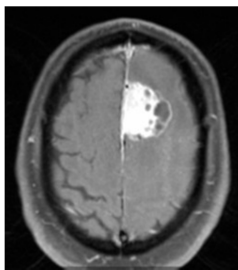
With this history patient was submitted to a Magnetic Resonance (MR) of the brain that showed an expansive lesion in the brain located in the left frontal lobe, adjacent to the medial line. It shows low signal at T1 (Figure 1A), high signal at T2 (Figure 1B) and Flair (1C) with moderated adjacent edema specially in the superior and middle frontal gyrus (Figure 1C). It looks as an extra-axial lesion and had a volume of 20 cc. With gadolinium injection the tumor was heterogeneous almost solid with cystic parts including adjacent impregnation of the dura of the midline (Figure 2).

Surgical treatment was done. A left frontal craniotomy was performed. The lesion was completely resected including the dura of the convexity that was invaded by the tumor. Postoperative period was uneventful, with resolution of the headache and no deficits. Patient was discharged 3 days after surgery.

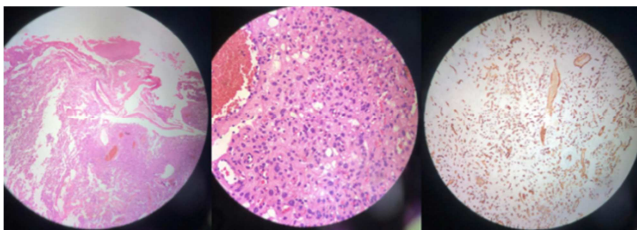
Pathology reveals the lesion was a hemangioblastoma (Figure 3). Patient made genetic exams and confirms that didn't have Von Hippel-Lindau disease. MR of the brain, almost 3 years of the surgery, reveals no tumor (Figure 4).



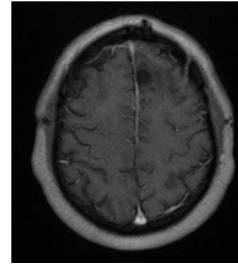
**Figure 1.** Magnetic resonance (MR) of the brain shows low signal at T1 (1A), high signal at T2 (1B) and Flair (1C) with moderated adjacent edema specially in the superior and middle frontal gyrus.



**Figure 2.** MR of the brain with gadolinium shows the tumor was heterogeneous almost solid with cystic parts and adjacent impregnation of the dura in the midline.



**Figure 3.** Pathologic examination confirms the tumor is a hemangioblastoma with their common characteristics. Left: Proliferation of blood vessels in the brain tissue. Note different calibers. Center: Note anisocariosis with low number of mitoses. Right: Immunohistochemical with CD34 antibody, which only stains the vessel wall. Note difference in vessel size.



**Figure 4.** T1 MR with gadolinium shows complete resection of the lesion.

### 3. Discussion

Hemangioblastoma (HBL) is a benign tumor, corresponds histologically to World Health Organization (WHO) grade I. [1], which predominantly affect adults, especially of the fifth decade of life, with a male predominance (1.3:1 ratio) [2, 3]. Commonly located in the posterior fossa of adult individuals, with a higher incidence in patients with retinocerebellar angiomas (von Hippel-Lindau disease). It is reported that its average age of occurrence is around 36 years. The youngest recorded patient is a 3-week-old male, while the oldest is a 80-year-old. [2, 3]

The supratentorial HBL are most commonly found in the frontal lobe of the cerebrum followed by parietal and temporal lobe [3], but it can be found in various locations including frontal, parietal, temporal, occipital, third ventricle, lateral ventricle, pituitary, pituitary stalk, suprasellar, hippocampus, falx cerebri, corpus callosum, meninges, and choroidal fissure. [4, 5]

Sporadic and nonfamilial cases account for about two thirds of hemangioblastomas overall, but only for 40% of supratentorial hemangioblastomas [6, 7]. However a few patients were initially diagnosed with sporadic hemangioblastoma and had no detectable VHL gene germline mutations, they subsequently developed another VHL-associated tumor and were finally diagnosed with VHL [6]. Mills et al. found that the rate of occurrence of VHL disease is significantly greater in patients with supratentorial hemangioblastoma, with 60% of patients receiving a diagnosis of VHL disease [8]. On reviewing the literature from 1902 to 2018, we found only 63 cases of supratentorial HBL without VHL [3, 6, 7]. In 18 cases they were frontal and only in 10 they had meningeal attachment, but in only 5 cases they were solid-cystic and of this only 1 was in the frontal, demonstrating the rarity of our case report. [3, 6, 7]

The clinical presentation of supratentorial HBL usually depends on the anatomical location and growth patterns. In general, supratentorial HBLs present with a long history of minor or no neurological symptoms that, in most cases, are followed by a sudden exacerbation [9, 10]. The most common pattern of growth was saltatory (72% of growing tumors), followed by exponential (22%) and linear (6%) [11]. Additionally HBLs are the only brain tumors associated with polycythemia [3]. Radiographically, the most common MR finding of HBL is a significantly enhancing mural nodule with an adjacent non-enhancing smooth cyst. On angiography, HBL demonstrate a highly vascular tumor blush within the avascular cyst and feeding vessels directed from the dural arteries.

Computed Tomography (CT) can detect the tumoral pseudocyst as higher density than that of the cerebrospinal fluid, while the nodule is isodense and typically enhances intensely, whereas the cystic component generally does not enhance on CT [9]. Proton MR studies show high mobile lipids peaks with no lactate peak, low creatine/phosphocreatine peak, increased, and choline-containing compounds in HBL [3].

Histologically HBL can be subclassified into two variants: the rarer cellular HBLs defined by zellballen-like cellular clusters of uniform tumor cells, and the more common reticular subtype showing abundant capillaries and stromal cells that may be glial fibrillary acidic protein (GFAP) immunoreactive leading to erroneous glioma diagnosis [9]. Several histogenetic theories have been proposed for this tumor, including derivation from vasoformative elements such as endothelium or pericytes, astrocytes, histiocytes or their precursor cells, or meningeal cells, but the cytogenesis of the stromal cells is still controversial [12]. No histologic difference exists between sporadic and VHL associated tumors [7].

Supratentorial hemangioblastomas are rare with little information in the literature to guide management [8]. Surgery is recommended if evidence of lesion progression, bleeding or clinical impairment, which is mostly associated to mass effect. During surgical resection, it is important to remove the nodules of the cystic lesions [10], the selective preoperative embolization is a safe, effective, and reliable adjuvant therapy for complete surgical resection [13]. Frozen sections may lead to an erroneous diagnosis because when the tissue is sectioned on a cryostat, the high lipid content of the stromal cells causes them to rupture, resulting in an artifactual resemblance to a fibrillary astrocytoma (12). Peyre et al. reported postoperative focal neurological deficits in 15% of patients, all of which ultimately improved [5].

Generally considered a radioresistant tumor, radiation therapy is restricted to cases of multiple lesions, deep location, subtotal resections, recurrence or postoperative hemorrhage, reporting tumor-control rates of 26% to 80% [10]. The vascular nature of these tumors and their high expression of vascular endothelial growth factor (VEGF), potentially makes it a target for antiangiogenic therapies with bevacizumab.

The most accepted recurrence rates are around 25% after surgical excision [10], with an age <30 years on initial diagnosis, presence of VHL disease, and multicentric involvement of the central nervous system being independent predictors of recurrence [13], needing MR as the regular follow-up method [2]. Complete resection of hemangioblastoma is curative and is associated with minimum morbidity and 2% mortality [3].

## 4. Conclusion

Hemangioblastoma is a rare tumor, especially in its supratentorial location, as showed by this uncommon description. However, this case reflects the importance of including HBL as a differential diagnostic allowing a better therapeutic planning, ensuring better prognosis and facilitating their treatment.

## References

- [1] Kansu T, Bower M, Waxman J, et al. World Health Organization Classification of Tumours of the Central Nervous System. Vol 16.; 2007. doi: 10.3171/2015.3.PEDS14619.
- [2] Yang B, Luan S, Cao X, Bao W. Supratentorial hemangioblastoma. *Neurosciences*. 2011; 16 (2): 150-152. doi: 10.1007/BF01402059.
- [3] Pandey S, Sharma V, Pandey D, Kumar V, Kumar M. Supratentorial haemangioblastoma without von Hippel-Lindau syndrome in an adult: A rare tumor with review of literature. *Asian J Neurosurg*. 2016; 11 (1): 8-14. doi: 10.4103/1793-5482.165782.
- [4] Lee CY, Chen SJ, Yang B, et al. Supratentorial haemangioblastoma without von Hippel-Lindau syndrome in an adult: A rare tumor with review of literature. *Korean J Pathol*. 2014; 6 (2): 462-465. doi: 10.1007/BF01402059.
- [5] Natural History of Supratentorial Hemangioblastomas in von Hippel-Lindau Disease. *Neurosurgery*. 2010; 67 (3): 577-587. doi: 10.1227/01.NEU.0000374846.86409.A7.
- [6] Wenting J, Ogawa Y, Ito J, Tominaga T. Suprasellar Hemangioblastoma Unrelated to von Hippel-Lindau Disease Successfully Treated through Extended Transsphenoidal Approach: Diagnostic Value of Von Hippel-Lindau Disease Gene-Derived Protein. *J Neurol Surgery, Part A Cent Eur Neurosurg*. 2017; 78 (3): 296-301. doi: 10.1055/s-0036-1582016.
- [7] Franco A, Pytel P, Lukas R V., Chennamaneni R, Collins JM. CNS hemangioblastomatosis in a patient without von Hippel-Lindau disease. *CNS Oncol*. 2017; 6 (2): 101-105. doi: 10.2217/cns-2016-0027.
- [8] Mills SA, Oh MC, Rutkowski MJ, Sughrue ME, Barani IJ, Parsa AT. Supratentorial hemangioblastoma: Clinical features, prognosis, and predictive value of location for von Hippel-Lindau disease. *Neuro Oncol*. 2012; 14 (8): 1097-1104. doi: 10.1093/neuonc/nos133.
- [9] She DJ, Xing Z, Liu Y, Cao DR. Supratentorial hemangioblastomas: Three case reports and review of the literature. *Clin Neuroradiol*. 2013; 23 (3): 243-247. doi: 10.1007/s00062-012-0183-9.
- [10] Rocha L, Noronha C, Taipa R, Reis J, Gomes M, Carvalho E. Supratentorial hemangioblastomas in von Hippel-Lindau wild-type patients—case series and literature review. *Int J Neurosci*. 2018; 128 (3): 295-303. doi: 10.1080/00207454.2017.1385613.
- [11] Lonser RR, Butman JA, Huntoon K, et al. Prospective natural history study of central nervous system hemangioblastomas in von Hippel-Lindau disease. *J Neurosurg*. 2014; 120 (5): 1055-1062. doi: 10.3171/2014.1.JNS131431.
- [12] Report AC. A Case Report and Review of the Literature. 2003: 1-3.
- [13] Lee CY, Chen SJ. Supratentorial leptomeningeal hemangioblastoma resection after tumor embolization. *Formos J Surg*. 2016; 49 (2): 78-81. doi: 10.1016/j.fjs.2016.02.002.