

# A Clinical Study in Cases of Trigeminal Neuralgia and Microvascular Decompression

Tushar Soni<sup>1</sup>, Mayuresh Rampurkar<sup>2,\*</sup>

Department of Neurosurgery, Smt. NHL Municipal Medical College & S. V. P. Hospital, Ahmedabad, Gujarat, India

## Email address:

tusharjagu@yahoo.com (T. Soni), mmrampurkar@gmail.com (M. Rampurkar)

\*Corresponding author

## To cite this article:

Tushar Soni, Mayuresh Rampurkar. A Clinical Study in Cases of Trigeminal Neuralgia and Microvascular Decompression. *International Journal of Neurosurgery*. Vol. 5, No. 1, 2021, pp. 19-23. doi: 10.11648/j.ijjn.20210501.15

**Received:** April 7, 2021; **Accepted:** April 21, 2021; **Published:** April 29, 2021

---

**Abstract:** Trigeminal neuralgia is one of the most painful conditions affecting area of face supplied by trigeminal nerve, which has a major impact on quality of life. There are few reports of trigeminal neuralgia in oriental population. The objective of this study is to evaluate of important clinical factors about trigeminal neuralgia and analysis of outcome after micro vascular decompression. This study includes 150 cases of trigeminal neuralgia treated with micro vascular decompression in VSGH and SVP hospital, Ahmedabad over the period of 10 years. In this study, the peak incidence of Trigeminal neuralgia was in 50-69 age groups with male preponderance (male-female ratio- 1.17:1). Most common complaint was typical trigeminal neuralgic pain along one side of face over a period of 2-5 years. The right side of face and V2+V3 segment of trigeminal nerve was involved more commonly. Intraoperatively, an arterial loop compressing trigeminal nerve was found in 90% of the patients. Duration of post-operative hospitalization in maximum patients was less than 5 days (60%) and there were no postoperative complications in 96% patients. The complications noted were pseudo-meningocele (2%), persistent facial pain (1.3%), transient facial weakness (2%), meningitis (0.66%) and death (1.3%). We can conclude from this study that, trigeminal neuralgia is a very painful disease of old age with slight male preponderance. Right sided v2v3 and v3 divisions are commonly involved with arterial loop compressing trigeminal nerve being the most common pathology. Micro vascular decompression is proved to be an effective modality of surgery with high success rate and very few complications.

**Keywords:** Trigeminal Neuralgia, Micro Vascular Decompression, Trigeminal Nerve, Neuralgic Pain, Pseudo-Meningocele

---

## 1. Introduction

Trigeminal neuralgia is an exemplary condition of neuropathic facial pain and also called "suicide disease" (Harvey Cushing) [1]. There are two main types: typical and atypical trigeminal neuralgia. More than 85% patients have typical trigeminal neuralgic pain.[2] The typical form results in seizure like episodes of severe, sudden, shock-like pain in one side of the designated areas of face that lasts for seconds to a few minutes. Groups of these episodes can occur over a few hours. The atypical form results in a constant burning pain that is less severe. Episodes may be triggered by any touch to the face. It is one of the most painful conditions, and has a major impact on quality of life. [2]

The pathology is believed to involve loss of the myelin around the trigeminal nerve. This may occur due to

compression from a blood vessel as the nerve exits the brain stem, multiple sclerosis, stroke, or trauma. Less common causes include a tumor or arteriovenous malformation. Trigeminal neuralgia is typically clinical diagnosis, but it is necessary to do MRI before proceeding to MVD for confirmation of vascular compression and ruling out other possible causes such as space occupying lesion. [2]

Treatment includes medication or surgery. The anticonvulsant carbamazepine or oxcarbazepine is usually the initial treatment, and is effective in about 80% of people. [3] Other options include lamotrigine, baclofen, gabapentin, and pimizide. [15] In those who do not improve or become resistant to other measures, a number of types of surgery may be tried. Percutaneous ablative procedures are relatively safer and simpler with short hospital stay. But they are having short time relief and higher recurrence with need of repeated interventions. Currently the micro vascular decompression

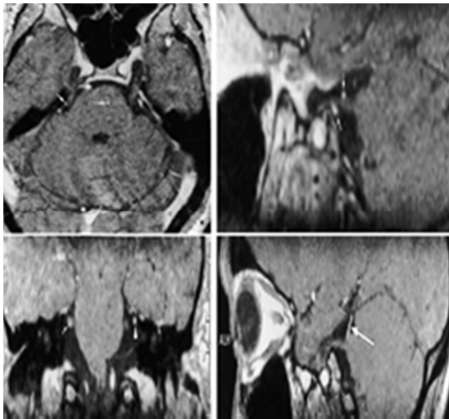
(MVD) is perceived as most effective treatment for trigeminal neuralgia.

This study includes 150 cases of trigeminal neuralgia treated with micro vascular decompression in view of study of important clinical factors like age and sex distribution, type of trigeminal pain, side and division of trigeminal nerve involved, vessel involved in the pathology and analysis of outcome and complications after micro vascular decompression.

## 2. Materials and Methods

This study is a retrospective as well as prospective interventional study and it consists of analysis of 150 cases of trigeminal neuralgia treated at Department of Neurosurgery, VS & SVP Hospital, Ahmedabad over the period of 10 years. The patients were included in the study between the age of 20-70 years of both sexes with typical trigeminal pain, which was not controlled by medications and who were fit and willing for surgery i.e. micro vascular decompression. Those patients who were controlled by medications, unfit and unwilling for surgery were excluded.

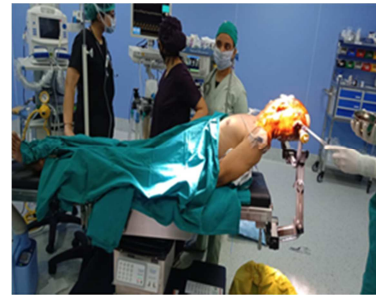The patients were assessed in detail by clinical history and general, systemic examination, and those patients require surgical intervention in the form of microvascular decompression admitted. The routine hematological and biochemical investigations as well as investigations required for anesthetics fitness were done. MRI of whole brain with trigeminal protocol was done in all patients to confirm vascular compression and to rule out mass lesion that could be a secondary cause of patient's clinical condition. All the patients studied were operated at the institute itself. Patient data was documented in case record form.



**Figure 1.** Vascular compression of right V nerve.

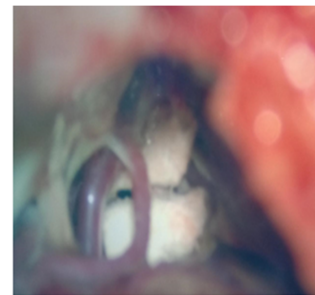
In our institute, micro vascular decompression of trigeminal nerve is the commonly performed procedure in cases of trigeminal neuralgia when indicated. The position used is supine with head rotated to side opposite to side of pathology. A vertical retro mastoid incision (5-7cm long) is made about half to one centimeter medial to the mastoid notch. The incision is carried down to the bone and craniectomy (around 2.5 cm x 2.5 cm) is done, exposing the transverse sinus superiorly and the sigmoid sinus laterally.

The dura opened in such a way to expose the junction between the superior and the lateral surfaces of the cerebellum.



**Figure 2.** Patient positioning for left sided Trigeminal neuralgia.

Under microscopic view, petrosal surface of cerebellum is retracted inferomedially with Layla retractor. The arachnoid membranes just inferior to superior petrosal vein are sharply opened and additional CSF is released. The superior petrosal vein is identified and, if absolutely necessary, it is coagulated and divided, if it prevents access to the entire length of the trigeminal nerve. The deeper arachnoid membranes should be cut with caution and dissected free of their entangled vessels. The trigeminal nerve located deeper and more medial than CN VII/VIII complex comes into view. The arachnoid over the nerve is dissected using sharp dissection and the whole nerve is exposed. In lower division TN, the offending vessel is usually the superior cerebellar artery compressing the nerve superiorly or anteriorly and in upper division TN, the anterior inferior cerebellar artery is often the offending artery. The whole complex of arterial loops is gently elevated from the nerve. A small Teflon patch has been interposed between the offending vessels and the nerve. When a vein is compressing the nerve and it cannot be separated from the nerve, it should be coagulated and divided. Care should be taken to see that too many veins are not sacrificed during the procedure. Hemostasis is achieved. In situations when there is suspicion of vasospasm as in case of atherosclerosis or old age, papavarine is applied locally to relieve vasospasm. After that, dura closed in water tight fashion to avoid csf leak and pseudomeningocele postoperatively. Muscle layers and subcutaneous tissue approximated in layers with absorbable suture materials (vicryl RB no-1). Skin closed with non-absorbable sutures (ethylon 3-0 cutting). Sterile antiseptic dressing is applied over suture line.



**Figure 3.** Teflon patch inserted between trigeminal nerve and compressing vessel.

Postoperative symptomatic improvement was assessed by comparing with preoperative symptoms. Patients were followed up till the end of the study for postoperative complications and recurrence.

### 3. Results

**Table 1. Age Incidence.**

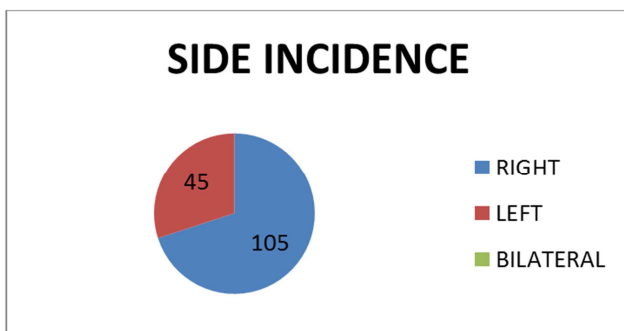
Age (years)	No. of Patients	Percentage (%)
21-30	3	2
31-40	15	10
41-50	30	20
51-60	54	36
>60	48	32

**Table 2. Sex Incidence.**

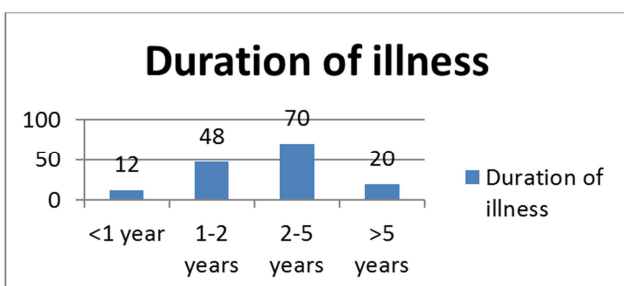
Sex	No. of patients	Percentage (%)
Male	81	54
Female	69	46

The age of the patients ranged from 28 years to 70 years in this study. The maximum incidence is in the 6th (36%) and 7rd (32%) decade of life. Average age of patients with TN is 54.30 years. There were 54% males and 46% females in our study group.

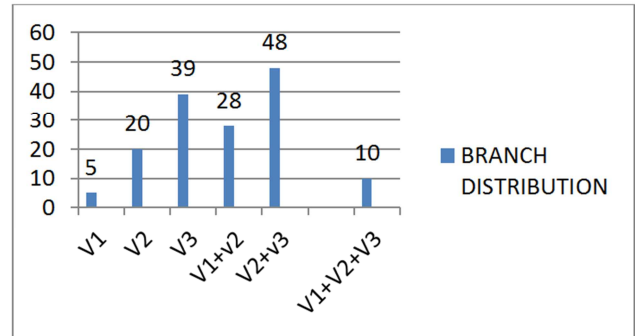
In this study the majority of patients had typical trigeminal facial pain. 46.6% of the patients had time period of 2-5 years between the onset of symptoms and 32% patients had symptoms for 1-2 years. Those patients who were symptomatic for less than 2 years were operated because they were having persistent pain in spite of medical management and adverse effects of medications. There is right sided preponderance in the present study, with right-left ratio 2.33:1.



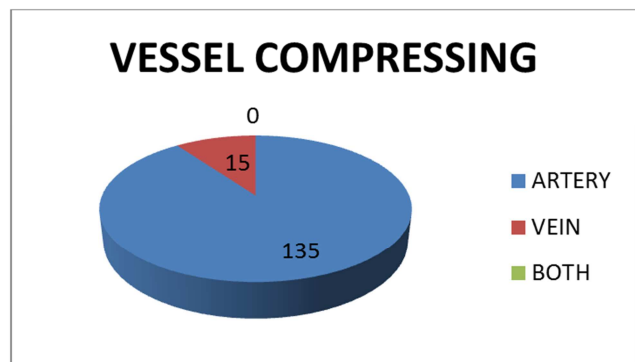
**Figure 4. Side incidence.**



**Figure 5. Duration of illness.**



**Figure 6. Branch distribution.**



**Figure 7. Vessel Compressing.**

In our study, it was found that V2V3 combinely involvement (32%) was commonest followed by V3 division alone (26%). The vessel compressing trigeminal nerve was found to be an arterial loop in 90% cases and vein compressing in 10% cases.

**Table 3. Complications.**

Complications	Percentage (%)
No complications	96
Wound infection	0
CSF leak	0
Meningitis	0.66
Pseudo-meningocele formation	2
Facial palsy	2
Post-operative hematoma	0
Post-operative collection/abscess	0
Persistent pain	1.3
Recurrence	0
Death	1.3

Out of 150 patients, 144 patients had immediate relief after surgery, 2 patients had relieved pain within two weeks, 2 patients were having persistent pain and 2 patients were died postoperatively. There were 6 patients with the history of radiofrequency ablation in the past 1-3 years. Among those, 2 patients were having delayed pain relief and 2 patients were having persistent pain after micro vascular decompression. So, we noticed that in patients who have already undergone percutaneous procedures did not experienced post-operative pain relief in a manner in which other patients experienced.

96% patients were having no complications. The complications noted were pseudo-meningocele (3 cases), persistent facial pain (2 cases), transient facial weakness (3

cases), and meningitis (1 case). There was death in 2 cases—one due to meningitis and other due to myocardial infarction. The Duration of postoperative hospitalization in maximum patients was less than 5 days (60%).

## 4. Discussion

The present study shows increased incidence in 6th decade which is comparative with the study of Aree Jainkittong et al (2011) [4], Yadav et al (2015) [5], Kathariya et al (2019) [6], Rai et al (2017) [7]. In this study, there is male preponderance with male to female ratio 1.17:1. In studies like Yadav et al (2015) and Rai et al (2017) results matches with our study with nearly similar male to female ratio. But in few studies like Aree Jainkittong et al (2011), Kathariya et al (2019) and Debta et al (2020)[16] show female preponderance in sex ratio in trigeminal neuralgia incidence in variable proportions. This may be due to different geographical areas and less sample size. There is right sided preponderance in the present study, with right-left ratio 2.33:1. Studies like Aree Jainkittong et al (2011), Yadav et al (2015), Debta Et al (2019), Kathariya et al (2019) matches with our study results with right side involvement being most common. But study of Rai et al (2017) have observed equal incidence of trigeminal pain on right and left side. In our study, we found that V2V3 division involvement (32%) was commonest followed by V3 division alone (26%). In all other studies except Rai et al, V2V3 division involvement was most common with variable involvement of other divisions. In study of Rai et al (2017), V2 division is most commonly involved. Findings from an Indian study of microvascular decompression (ISMD), [8] arteries are involved in 84% cases, veins in 5% cases and both in 11% cases. In study of S. Peker et al (2009), arterial loop was found to be involved in 86% and venous loop in 14% cases.[9] From findings of Aqueel Pabaney (2020) [10], arterial loop compressing trigeminal nerve found in 85% cases, vein compressing in 12% cases and both in 3% cases. Findings from present study correlates with these studies as arterial compression being the most common pathology involved.

In our study 96% patients were having no complications. The complications noted were pseudo-meningocele (2%), persistent pain (1.3%), transient facial weakness (2%), meningitis (0.66%) and death (1.3%). In various studies at different times and at different institutes various types of complications observed in different proportions. In study of Kolluri et al [11] (1984), facial palsy was observed in 7% patients, ataxia and diplopia in 4% patients, deafness in 19% patients, recurrence in 16% patients and death in 8% patients. In study of Barker et al [12] (1996), deafness observed in 1.55% patients, recurrence in 2% and death in 0.2% patients. In study of Slettebo et al (1997) [13], persistent pain observed in 8% patients, recurrence in 8% and death in 4% patients. In study of Sindou et al [14] (2006), persistent pain observed in 15% patients and recurrence in 3% patients. In study of Gunther et al (2009), csf leak was observed in 1%, meningitis in 1%, pseudomeningocele in 6%, facial palsy in 1%, persistent pain in 11% recurrence in 8% and death in 3%

cases.

## 5. Conclusion

Trigeminal neuralgia is a very painful disease of old age causing episodes of shock like transient multiple episodes of electric shock like or cutting pain along distribution of trigeminal nerve.

Our study observed it is common in 5<sup>th</sup> and 6<sup>th</sup> decade males and females with slight male preponderance (1.17:1). Right side and V2V3 followed by V3 divisions are commonly involved and arterial loop compressing trigeminal nerve being the most common pathology. Patients are primarily managed with medical management with anticonvulsants. Very old patients and which are unfit for surgery can be managed with percutaneous procedures which give short term relief and repeated interventions required in majority of patients. Those with uncontrolled pain with medications and long duration of symptoms affecting daily living are candidates for micro vascular decompression which is proved to be an effective modality of surgery with very few postoperative complications.

## References

- [1] Nair RSK. Trigeminal neuralgia. Editorial Calicut Med J. 2004; 2 (1): e10.
- [2] Adams CBT. Trigeminal neuralgia: pathogenesis and treatment. Br J Neurosurg 1997; 11: 493±5.
- [3] Khan OA. Gabapentin relieves trigeminal neuralgia in multiple sclerosis patients. Neurology. 1998; 51 (2): 611–4.
- [4] Aree Jainkittong<sup>1</sup>, Vilaiwan Aneksuk<sup>1</sup> and Robert P. Langlais<sup>2</sup> <sup>1</sup> Department of Oral Medicine, Faculty of Dentistry, Chulalongkorn University, Bangkok, Thailand; <sup>2</sup> Department of Dental Diagnostic Science, The University of Texas Health Science Center at San Antonio, San Antonio, TX, USA doi: 10.1111/j.1741-2358.2011.00530.x Trigeminal neuralgia: a retrospective study of 188 Thai cases.
- [5] Sunil Yadav <sup>1</sup>, Hitesh-Chander Mittal <sup>2</sup>, Akash Sachdeva <sup>3</sup>, Ajay Verma <sup>4</sup>, Vikas Dhupar <sup>5</sup>, Anita Dhupar <sup>6</sup> Clin Exp Dent. 2015; 7 (1): e40-4. Retrospective study of patients with trigeminal neuralgia e40 Journal section: Oralfacial pain-TMJD Publication Types: Research A retrospective study of 72 cases diagnosed with idiopathic trigeminal neuralgia in indian populace.
- [6] Kathariya G, Chaurasia A, Khan N, Iqbal J. Prevalence of trigeminal neuralgia in Indian population visiting a higher dental care center in North India. Natl J Maxillofac Surg 2019; 10: 195-9.
- [7] Rai A, Kumar A, Chandra A, Naikmasur V, Abraham L. Clinical profile of patients with trigeminal neuralgia visiting a dental hospital: A prospective study. Indian J Pain 2017; 31: 94-9.
- [8] McLaughlin MR, Jannetta PJ, Clyde BL, Subach BR, Comey CH, Resnick DK. Microvascular decompression of cranial nerves: lessons learned after 4400 operations. J Neurosurg 1999; 90: 1±8.

- [9] Peker S, Dinçer A, Necmettin Pamir M. Vascular compression of the trigeminal nerve is a frequent finding in asymptomatic individuals: 3-T MR imaging of 200 trigeminal nerves using 3D CISS sequences. *Acta Neurochir (Wien)*. 2009 Sep; 151 (9): 1081-8. doi: 10.1007/s00701-009-0329-y. Epub 2009 May 5. PMID: 19415176.
- [10] Aqueel Pabaney, (2020) <https://doi.org/10.18791/nsatlas.v6.ch01.1>.
- [11] Kolluri S, Heros RC. Microvascular decompression for trigeminal neuralgia. A five-year follow-up study. *Surg Neurol*. 1984 Sep; 22 (3): 235-40. doi: 10.1016/0090-3019.
- [12] Barker FG 2nd, Jannetta PJ, Bissonette DJ, Larkins MV, Jho HD. The long-term outcome of microvascular decompression for trigeminal neuralgia. *N Engl J Med*. 1996 Apr 25; 334 (17): 1077-83. doi: 10.1056/NEJM199604253341701. PMID: 8598865. (84) 90005-3. PMID: 6463831.
- [13] Slettebø, H., Eide, P. K. A prospective study of microvascular decompression for trigeminal neuralgia. *Acta neurochir* 139, 421–425 (1997). <https://doi.org/10.1007/BF01808878>.
- [14] Sindou M, Leston J, Howeidy T, Decullier E, Chapuis F. Micro-vascular decompression for primary Trigeminal Neuralgia (typical or atypical). Long-term effectiveness on pain; prospective study with survival analysis in a consecutive series of 362 patients. *Acta Neurochir (Wien)*. 2006 Dec; 148 (12): 1235-45; discussion 1245. doi: 10.1007/s00701-006-0809-2. Epub 2006 Sep 18. PMID: 16804643.
- [15] Obermann M, Yoon MS, Sensen K, et al. Efficacy of pregabalin in the treatment of trigeminal neuralgia. *Cephalalgia*. 2008; 28 (2): 174–81.
- [16] Debta, P, Sarode, G, Sarode, S, et al. Natural history of trigeminal neuralgia — A hospital-based retrospective study. *Oral Dis*. 2020; 26: 647– 655. <https://doi.org/10.1111/odi.13263>.

## Biography



**Tushar Soni** MS, M. Ch (Neurosurgery)

Dr. TUSHAR V. SONI is a professor and head of unit at Department of neurosurgery, SMT. NHL Municipal Medical College & S. V. P. Hospital, Ahmedabad. He is a well-known consultant neurosurgeon in Ahmedabad. He has published several articles in national and international journals.



**Mayuresh Rampurkar**

Dr. Mayuresh Rampurkar is a M. B. B. S., M. S. (GENERAL SURGERY) and doing M. CH. Neurosurgery as a 3<sup>rd</sup> YEAR RESIDENT at,, SMT. NHL Municipal Medical College & S. V. P. Hospital, Ahmedabad under guidance of Dr. Tushar Soni Sir.