



Cystic Craniopharyngiomas Treated by Ommaya Reservoir Implantation About 4 Cases Including 2 Cases of Intracystic Injection of Bleomycin

Denléwendé Sylvain Zabsonre^{*}, Eustache Kienou, Joseph Biogo, Louis Junior Comboigo, Wendlasida Serge Pacome Arnould Yameogo, Henri Lankoande, Abdoulaye Thiombiano, Abdoulaye Sanou, Yacouba Haro, Inoussa Zoungrana, Abel Kabre

Neurosurgery Department of Yalgado Ouedraogo Teaching Hospital, Ouagadougou, Burkina Faso

Email address:

dzabsonre@gmail.com (Denléwendé Sylvain Zabsonre), ekienou@gmail.com (Eustache Kienou), joseph_biogo@yahoo.fr (Joseph Biogo), comboigoslouisjunior@gmail.com (Louis Junior Comboigo), pacomeseergey@yahoo.fr (Wendlasida Serge Pacome Arnould Yameogo), lankoandehenri83@gmail.com (Henri Lankoande), th_abdoulaye@yahoo.fr (Abdoulaye Thiombiano), sanou_abdou2002@yahoo.fr (Abdoulaye Sanou), yaksterharo@yahoo.fr (Yacouba Haro), zounggranainouss@gmail.com (Inoussa Zoungrana), kabrel@yahoo.fr (Abel Kabre)

^{*}Corresponding author

To cite this article:

Denléwendé Sylvain Zabsonre, Eustache Kienou, Joseph Biogo, Louis Junior Comboigo, Wendlasida Serge Pacome Arnould Yameogo, Henri Lankoande, Abdoulaye Thiombiano, Abdoulaye Sanou, Yacouba Haro, Inoussa Zoungrana, Abel Kabre. Cystic Craniopharyngiomas Treated by Ommaya Reservoir Implantation About 4 Cases Including 2 Cases of Intracystic Injection of Bleomycin. *International Journal of Neurosurgery*. Vol. 7, No. 1, 2023, pp. 7-12. doi: 10.11648/j.ijjn.20230701.12

Received: March 23, 2023; **Accepted:** April 14, 2023; **Published:** May 10, 2023

Abstract: *Introduction.* Cystic craniopharyngiomas are the most common form of craniopharyngiomas. The treatment is still debated. The less aggressive and multidisciplinary approach is more recommended. *Methods.* We describe 4 cases of cystic craniopharyngiomas managed in our department by implantation of an Ommaya reservoir. The diagnosis was retained on imaging and in front of the appearance of the cyst puncture fluid. Intracystic chemotherapy with bleomycin was performed in 2 cases. *Results.* Patient's age was 3, 34, 51 and 65 years. There were 2 female and 2 male patients. Clinical signs were dominated by headache (4 cases) and visual disturbances (4 cases). The Ommaya reservoir was placed with an endoscope in 2 cases. Postoperative insipid diabetes was noted in these 2 cases. A puncture of the Ommaya reservoir was performed on average every 3 weeks (2 cases) in the absence of Bleomycin. Infection was noted in these 2 cases. The evolution was favorable in 3 cases including the 2 cases of Bleomycin injection. *Conclusion.* Ommaya reservoir implantation was a satisfactory alternative to surgical excision of craniopharyngiomas. The use of the endoscope increased the risk of developing insipid diabetes. Close punctures of the reservoir increased the risk of infection. Intra-cystic Bleomycin stopped the punctures of the reservoir.

Keywords: Craniopharyngioma, Ommaya Reservoir, Bleomycin

1. Introduction

Craniopharyngiomas are histologically benign embryonic tumors. They originate in the pituitary stalk from remnants of Rathke's pouch. These are rare tumors with an incidence of about 20-25 cases per year in France [12]. Their diagnosis is often made late in adulthood after the appearance of the first sign that is not always recognized early. Cystic craniopharyngiomas are the most common form of craniopharyngiomas [3, 5].

The treatment is still debated. For many decades, neurosurgeons considered that complete removal of this histologically benign lesion was the best option, but it is a major surgery with the appearance of sequelae (endocrine and neuro-intellectual) sometimes incompatible with a good quality of life. The recurrence rate is close to 50% and these recurrences are possible even in case of macroscopically total excision [3, 5]. In addition, despite the contribution of microsurgical techniques, this "total" excision is not always without risk. When total removal is not possible, high-energy

external radiotherapy may reduce the risk of recurrence in adults. In children, it has a high risk of side effects. All these situations have led to the modification of craniopharyngiomas therapeutic approach towards a less aggressive and multidisciplinary approach (neurosurgeon, endocrinologists, radiotherapists...). It is in this context that placing an Ommaya reservoir and intracystic bleomycin have been used to potentially reduce the signs of cystic craniopharyngiomas [12]. We report four cases of cystic craniopharyngiomas that we treated with an Ommaya reservoir implantation, two of which benefited from intracystic bleomycin.

2. Method

We describe 4 cases of cystic craniopharyngiomas managed by the placement of an Ommaya reservoir in the neurosurgery department of Yalgado Ouedraogo University Hospital in Ouagadougou. A cure of intracystic chemotherapy with bleomycin was performed in 2 of these cases. Each cure included ten (10) intra cystic injection sessions of 3 mg of bleomycin every 48 hours.

The positive diagnosis of cystic craniopharyngioma had been made by the appearance of the lesion on medical imaging (CT, MRI) and the macroscopic appearance of the cyst fluid puncture. On medical imaging, it was a heterogeneous sellar and suprasellar tumor process comprising a small fleshy portion with calcifications and a large cystic portion with an eggshell appearance. The macroscopic appearance of the cyst puncture fluid was that of a black viscous substance with the appearance of "engine drain oil."

3. Results

3.1. Description of the First Case

Fifty-one-year-old patient, electro-mechanic, consulted in February 2015 for headaches associated with visual disorders and sleep disorders (such as alternating drowsiness and insomnia) that would evolve for four months. Physical examination noted a psychomotor slowdown. Cranioencephalic CT scan made it possible to objectify a heterogeneous sellar and suprasellar tumor process comprising a small fleshy portion with calcifications and a large cystic portion with an eggshell appearance in favor of a craniopharyngioma as well as triventricular hydrocephalus (Figure 1).

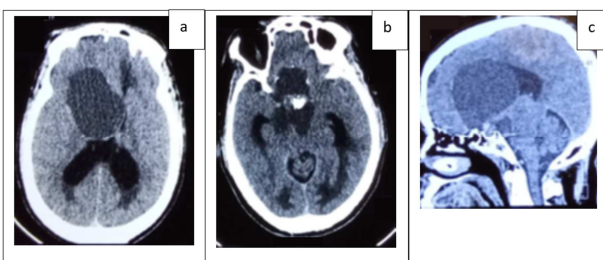


Figure 1. Preoperative CT scan of the first case. Axial section without injection of contrast product showing the cyst and hydrocephalus (a); calcification (b). Sagittal reconstruction with contrast injection showing the cyst and calcification (c).

A puncture of the craniopharyngioma cyst was performed about 1 month after the CT scan bringing back a viscous blackish liquid appearance "engine drain oil." Histopathological examination of the cyst fluid puncture concluded to a chronic macrophage inflammatory fluid. On the fourth day after this cyst puncture, clinically there was an amelioration of the signs and at the control CT was noted a decrease in the size of the cyst associated with a small bifrontal pneumocephaly. Five months after this puncture, headaches and sleep disorders reappeared. Cranioencephalic computed tomography made it possible to objectify lesions superposable to those of the CT scan before the puncture of the cyst. An Ommaya reservoir was laid freehand by a drill hole in the right frontal. The day after this procedure, a control CT scan made it possible to objectify the catheter in the cystic (Figure 2). The iterative punctures of the reservoir carried out every 3 weeks in front of the appearance of headaches, brought back on average 40 ml of liquid aspect "engine drain oil" per puncture. The patient had become asymptomatic a few days after each puncture and was engaged in normal work activity for 4 years. Four years after the placement of the Ommaya reservoir appeared visual disturbances and left hemiplegia (muscle strength at 1/5 in the thoracic limb and 2/5 in the pelvic limb). A new CT scan showed a small cyst (compared to the preoperative CT scan) and the catheter in place (Figure 2). A cystography performed in May 2019 did not object to a leakage of the contrast medium (Figure 2). One course of intracystic chemotherapy with bleomycin was performed. The evolution was marked by a regression of visual disorders and left hemiplegia with a muscular strength that increased to 4/5 in both limbs. No drain of the reservoir has been carried out thereafter to date. The control cranioencephalic CT scan performed two months after the injections of bleomycin made it possible to objectify an almost complete collapse of the cyst (Figure 2).

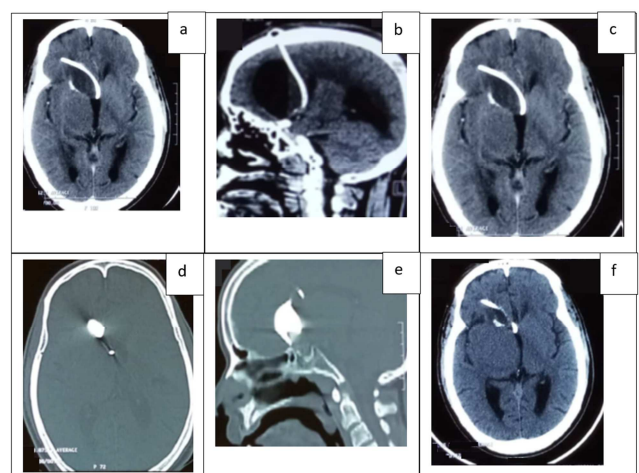


Figure 2. Postoperative CT scan of the first case. Images without injection of contrast on Day 1 of the reservoir implantation: axial section (a); Sagittal reconstruction (b) showing the catheter in the cyst. 4 years after reservoir placement: axial section without contrast (c) showing the catheter in place in a small cyst; Axial contrast cystography (d) and sagittal reconstruction (e) not showing leakage of contrast product. 2 months after intracystic bleomycin: axial section without injection of contrast (f) showing an almost complete drying of the cyst.

3.2. Description of the Second Case

Patient of 34-year student midwife consulted in October 2015 for moderate headaches associated with drowsiness, visual disturbances of progressive worsening for 03 months. The physical examination noted a psychomotor slowdown, a decrease in visual acuity especially on the right and bilateral papillary edema. The CT scan and then the brain MRI images were in favor of a cystic craniopharyngioma. The MRI showed a sellar and suprasellar cystic lesion coming into contact with the midbrain with an "eggshell" appearance of its wall (Figure 3). Pituitary hormone balance (Prolactinemia, T3, T4, TSH, FSH/LH, Cortisol, Somatomedin) was normal. An Ommaya reservoir was placed in April 2016 with the rigid endoscope at zero degrees through a right frontal drill hole.

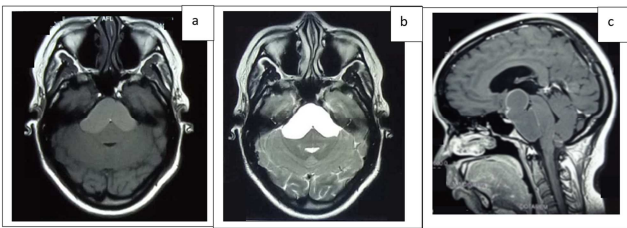


Figure 3. Preoperative MRI of the second case. Axial cross-section images T1-weighted sequence without contrast (a), axial section in T2-weighted sequence (b); Sagittal section with contrast (c) showed a sellar and suprasellar cystic lesion going into contact with the midbrain with an appearance of its wall in "eggshell" in favor of a craniopharyngioma.

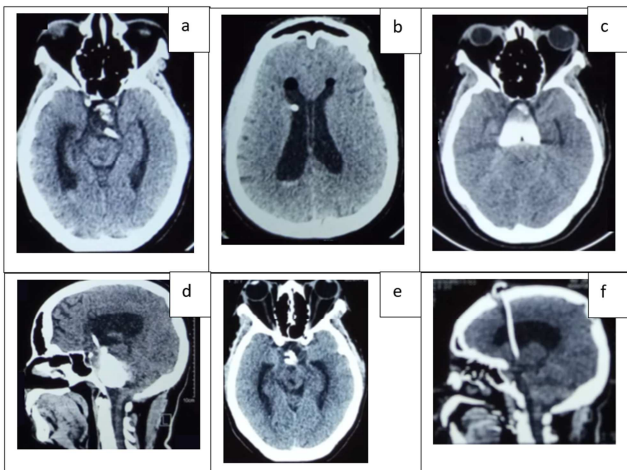


Figure 4. Postoperative CT scan of the second case. Images without contrast on day 1 of the reservoir implantation: axial section (a, b) showing the catheter in the cyst that is collapsed. Images made 11 months after reservoir placement: axial contrast cystography (c) and sagittal reconstruction (d) showing no contrast product leakage. Images without contrast made 2 years after the treatment of Bleomycin (without puncture of the reservoir): axial section (e) sagittal reconstruction (f) showing an almost complete drying of the cyst.

The cystic puncture brought back a viscous blackish liquid that looked like "engine drain oil." Transient insipid diabetes (on desmopressin) and left hemiparesis occurred postoperatively. These signs quickly regressed after a few days. Control CT on the second postoperative day was

satisfactory (Figure 4). Thereafter, punctures of the Ommaya reservoir were performed on average every 2 to 3 weeks when the patient became symptomatic (headache). Six months after the placement of the Ommaya reservoir, the patient presented a first generalized epileptic seizure and skin suppuration at the puncture site of the reservoir. This suppuration is cured after one month of local dressings associated with probabilistic systemic antibiotic therapy. Another epileptic seizure of the same type occurred about 3 weeks after the first. No seizures occurred after healing of skin suppuration. In February 2017, a cystography performed had made it possible to objectify the absence of leakage of the contrast product (Figure 4) which made it possible to perform one cure of intracystic injections of Bleomycin. The clinical signs have improved, hence the cessation of reservoir punctures to this day. The patient was able to complete her midwifery studies and is currently in service as such. The cranioencephalic computed tomography of January 2019 objectified the drain in place and the absence of a cyst (Figure 4).

3.3. Description of the Third Case

Sixty-five-year-old patient, retired, consulted in January 2019 for chronic headaches evolving intermittently for several years. These headaches would have been exacerbated for two weeks associated with insomnia, visual disorders. She reported as a history of high blood pressure and hypothyroidism followed for several years. The physical examination noted bradycardia at 50 beats per minute, psychomotor slowdown, and anterograde amnesia. The CT scan and then the brain MRI was in favor of a cystic craniopharyngioma. MRI objectified a sellar and suprasellar lesion, multilobar, heterogeneous with a tissue component and a large suprasellar cystic component with a left temporal extension. There was moderate supratentorial hydrocephalus (Figure 5).

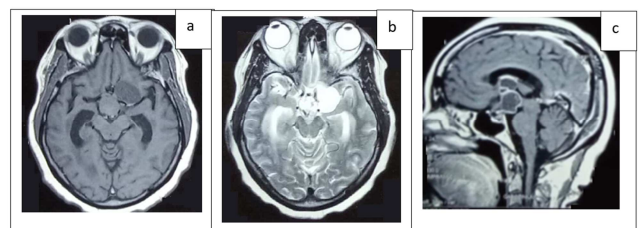


Figure 5. Preoperative MRI of the third case. Axial cross-section images T1-weighted sequence without contrast (a), axial section in T2-weighted sequence (b); Sagittal section with contrast (C) showed a sellar and suprasellar lesion, multilobar, heterogeneous with a tissue component and especially a suprasellar cystic component with a left temporal extension in favor of a craniopharyngioma. There was moderate supratentorial hydrocephalus.

A week after the MRI, an Ommaya reservoir was placed through a drill hole in the frontal right with the help of a rigid endoscope at zero degrees. The cystic puncture brought back a viscous blackish liquid that looked like "engine drain oil." On the first postoperative day (Day 1), the evolution was simply marked by the persistence of preoperative signs without any complications. The first postoperative day control

cranioencephalic computed tomography was satisfactory to objectify the end of the catheter in the cyst with a decrease in the size of the cyst, moderate pneumocephaly in the right frontal, absence of hemorrhagic complications (Figure 6). Enoxaparin isocoagulant dose was initiated on the second postoperative day based on the patient's cardiovascular history. On the third postoperative day there was somnolence and insipid diabetes, which persisted intermittently on desmopressin. A CT scan performed on the fourth postoperative day in front of this clinical aggravation (increasing drowsiness) made it possible to objectify an intracystic hemorrhage (Figure 6). Enoxaparin was stopped after a cardiology opinion. At the ninth postoperative day, these are added hydro electrolyte disorders such as hyponatremia and hypokalemia. Multidisciplinary care (neurosurgeon, cardiologists, endocrinologists, resuscitators) has been established for the correction of these various disorders. On the tenth postoperative day, there was also dyspnea and severe clinical and biological infectious syndrome. Chest X-rays objectified signs of massive right lung disease. At the thirty-sixth postoperative day, the disorders of consciousness worsened. A cranioencephalic CT scan performed on the thirty-sixth postoperative day had made it possible to objectify a resorption of the intracystic hemorrhage without other intracranial aggravation signs (Figure 6). The patient died on the thirty-ninth postoperative day.

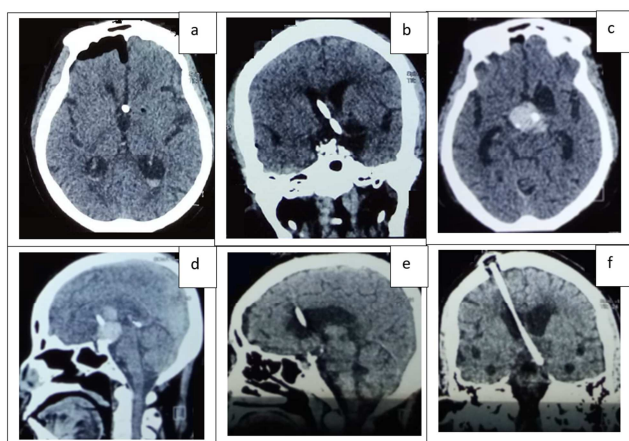


Figure 6. Postoperative CT scan of the third case. Images without contrast on day 1 of the installation of the reservoir: axial section (a), coronal reconstruction (b) showing the catheter in the cyst that is collapsed, a right frontal pneumocephaly. Images without contrast on day 4 of the installation of the reservoir in axial section (c), sagittal reconstruction (d) showing an intracystic hematoma. Images without contrast on day 39 of the installation of the reservoir in sagittal reconstruction (e) and coronal (f) showing a complete resorption of the intracystic hematoma and collapse of the cyst.

3.4. Description of the Fourth Case

Three-year-old patient, with no known pathological history, consulted in January 2020 for chronic headaches associated with visual disturbances such as a decrease in visual acuity and difficulty in moving the left hemi body all of progressive installation on 3 months. Physical examination had found a macrocrania with a head circumference at 55 cm, a decrease in visual acuity with bilateral papillary edema, left hemiplegia with a muscular force of 2/5. Cranioencephalic computed

tomography made it possible to objectify a sellar and suprasellar cystic lesion with peripheral calcifications in favor of a cystic craniopharyngioma associated with hydrocephalus (Figure 7). Pituitary hormone balance was normal. One week after the scan was performed, an Ommaya reservoir was placed freehand through a drill hole in the right frontal. The cystic fluid had an "engine drain oil" appearance. Subsequent punctures of the Ommaya reservoir were performed when it became symptomatic (headache) on average every 3 to 4 weeks. The consequences were marked by suppuration of the skin in front of the Ommaya reservoir exposing it and causing its removal two months after its installation. One month later, the patient presented with a left hemiplegia with muscle strength of 2/5 in the thoracic limb and 3/5 in the pelvic limb. The cranioencephalic CT scan performed in April 2020 made it possible to objectify a lesion almost identical to that of the initial CT scan. Another Ommaya reservoir was implant again, this time through a drill hole in the left frontal. On the first day after the placement of the second reservoir, the left hemiplegia had regressed (muscle strength increased to 3/5 in the thoracic limb and 4/5 in the pelvic limb). At the fourth day after the second reservoir was placed, on the CT control, the cyst had decreased in volume and the catheter was intracystic with its distal end that appeared to be extra cystic lodged in the preponic cistern (Figure 7). On January 20 21, the patient presented with a rapid worsening of his left hemi body motor deficit and visual disturbances. A CT scan made it possible to objectify a reconstruction of the cyst. The catheter was extra cystic. The catheter was repositioned with the help of fluoroscopy (front and profile images) intraoperatively. The postoperative follow-up was simple. Preoperative clinical signs have regressed. The CT scan carried out three months later showed an almost complete collapse of the cyst (Figure 7).

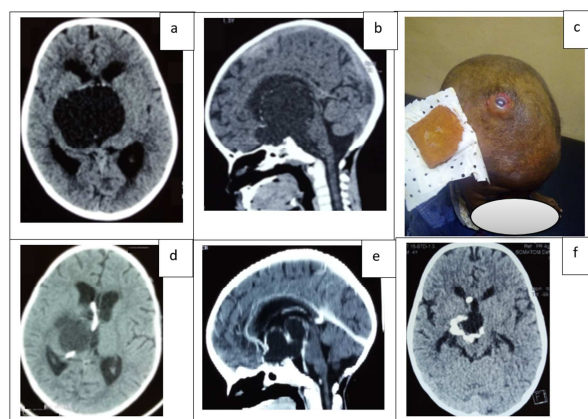


Figure 7. Pre- and post-operative images fourth case. Preoperative CT scan without contrast, axial section (a), sagittal reconstruction (b) showing a cystic sellar and suprasellar lesion with peripheral calcifications in favor of craniopharyngioma associated with hydrocephalus. Photo of suppuration/cutaneous necrosis in the second postoperative month that motivated the removal of the reservoir (c). CT scan without contrast on day 4 of the second placement of the reservoir (replacement of the first who was infected) in axial section (d) and sagittal reconstruction (e) showing the catheter intracystically with its distal end which appeared to be extra-cystic housed in the pre-pontic cistern. CT scan without injection of contrast medium 3 months after repositioning of the second reservoir in axial section (f) showing an almost complete collapse of the cyst.

4. Discussion

Craniopharyngiomas are rare tumors. They represented 5.6% of all brain tumors operated in our department [16] and 4% of intracerebral tumors in Dakar [13]. Three patients in our series were adults. It is an embryonic tumor that may be more common in children [2, 3, 5]. However, several authors [4, 7, 11, 13] have also published cases diagnosed in adulthood. It is a benign tumor of slow and insidious evolution that can be diagnosed in adulthood when the first signs appear. Deghima and al [4] reported 3 cases in adults (21, 22, 23 years); in whom they found an increase in the volume of craniopharyngiomas under estrogen and / or growth hormone.

The positive diagnosis of cystic craniopharyngioma was made in our series in front of its typical CT scan appearance (lesion of the sellar region with a fleshy component with calcifications and a large cystic portion with an eggshell appearance) and the macroscopic appearance of the puncture fluid (a viscous blackish liquid "engine drain oil" appearance). Histologic confirmation could not be made on the cystic fluid (without the fleshy portion) of our first case. This led us to no longer transmit the cyst puncture liquid of the 3 other cases in anatomy pathology. In a study done in Dakar [13] the diagnosis of craniopharyngiomas was retained only on the basis of the results of medical imaging in 9 out of 11 cases. Imaging revealed three components (cystic, fleshy, calcification) in 45% of patients and two components (cystic, fleshy) in 36% [13]. This diagnosis (clinical radio) is easy at an advanced stage as was the case in our series. This is not the case at the early stage where a differential diagnosis can be made with prolactinoma, hence the interest of pathological anatomy [12]. There are two main histological and clinical subtypes of craniopharyngioma which are pituitary adamantinoma (classical form) and papillary craniopharyngioma. The adamantine histologic type was most common in most series [13, 15]. Xu and al [15] noted 53 adamantine cases and 14 papillary cases. In medical imaging it is interesting to specify the position of the craniopharyngioma in relation to the chiasma and / or sellar diaphragm and the hypothalamus. This may have implications for the treatment decision. Park and al [11] had 79.7% retro chiasmatic forms. Compared to the sellar diaphragm, it is distinguished a grade 0 (infra diaphragmatic lesion and distant from the hypothalamus) whose surgery is more indicated transsphenoidal; a grade 1 (sub or supradiaphragmatic, in contact with the hypothalamus) that can be operated transsphenoidal, pterional or subfrontal and a grade 2 (supradiaphragmatic, hypothalamus invasion) operable pterionally, subfrontal, transcallosal or these combined routes [12]. Transpetrous approach has been used in retro chiasmatic craniopharyngioma [17]. These approaches should be done with optical magnification (microscope, endoscope...) and / or monitoring of the optic nerve as much as possible [10, 17].

"Complete" surgical removal is a real challenge with several sometimes fatal complications [3, 12]. In addition, recurrences after "complete" surgical removal are common [1, 3, 12]. Park and al [11] performed 48.4% transcranial

approaches and 51.6% transsphenoidal with 68.8% "complete" resection. Al Shail and al [1] had 25% recurrence among their cases of "complete" excision. Lagha and al [8] had 3 cases of recurrence out of 10 patients operated by trans sphenoidal approach. Thiam and al [13] out of a series of 11 patients, 7 had benefited from a tumor approach (subfrontal 3, transsphenoidal 2, pterional and temporo-parieto-frontal 1) and 4 from a ventriculoperitoneal shunt of the cerebrospinal fluid (CSF). Excision was total in 2 patients, partial in 4 and a simple biopsy was performed 1 time. The evolution was good in 3 cases. There have been 3 deaths, 1 case of insipid diabetes and 2 recurrences [13].

To minimize the risks associated with surgical excision, several attitudes have been proposed: radiotherapy alone or in addition to surgery [7-9, 11, 14]; puncture drainage of the cyst through a reservoir with or without intracystic chemotherapy (interferon, bleomycin) [3, 5]; immunotherapy (tocilizumab with or without bevacizumab) [6]. After an intracystic injection of a radioactive isotope through Rickam's reservoir, some [7] had 2 deaths (6.25%) and found that the dose of the radioisotope has an important role in the appearance of various disorders, the most serious of which with an irradiation dose of 300 Gray to the inner wall of the cyst. For other authors [8], the injection of the radioisotope gave rather satisfactory results: 4 cysts had completely disappeared, 5 had decreased by 80% and 1 had remained stationary.

Although radiation therapy in adults is valid, it has a high risk of side effects in children. Proton therapy is more indicated in children [12, 14]. Intracystic bleomycin is used to potentially reduce side effects associated with cystic craniopharyngioma [5]. Bleomycin initially administered as an antibiotic is known to be very active in the treatment of squamous cell carcinoma of the skin. It was proposed by Umezawa in 1966 in the management of craniopharyngiomas since they have the same embryonic origin as squamous cell carcinoma [3]. Subsequently, several authors [3, 5] have published satisfactory results of the use of bleomycin in the management of cystic craniopharyngiomas.

We carried out the installation of Ommaya reservoirs with results that we considered satisfactory. The case of death was due to other comorbidities (bradycardia, hypothyroidism, high blood pressure) that the patient had preoperatively. Other authors [7] had 2 deaths in their study, including 1 of whom causes unrelated to craniopharyngiomas or its treatment. We noted 2 complications related to our therapeutic attitude: insipid diabetes and infection of the skin in front of the reservoir. Infection of the skin in front of the reservoir was observed in cases where the reservoir puncture was close together (every 3 weeks on average). This motivated to add Bleomycin which made it possible to dry out the cyst and stop the punctures. However, bleomycin poses a problem of its availability (geographical and financial) in our country. Postoperative insipid diabetes has been noted by other authors [2, 9, 13] with rates up to 46.8% [2]. As was the case in these studies [2, 9, 13], this diabetes responded well to desmopressin in our series. In our series, transient insipid diabetes occurred in patients in whom the reservoir was placed

with the help of the endoscope. We only have a rigid endoscope at zero degrees. Its use does not offer a maximum field of view. Attempts to enlarge this visual field by untimely tilts can cause cerebral contusions by the rest of the endoscope stem which is intracerebral, but escapes our visual control. Thus, in addition to insipid diabetes, one patient presented postoperative hemiparesis, which subsequently regressed. To minimize this risk of postoperative deficit, we used fluoroscopy in our fourth case as an intraoperative guide for the placement of the reservoir. The suites were simple. Other authors have placed intracystic catheters in stereotactic conditions [7-9].

5. Conclusion

Ommaya reservoir was a satisfactory alternative to surgical removal of craniopharyngiomas. The use of the rigid endoscope at zero degrees increased the risk of developing insipid diabetes. Punctures close to the reservoir increased the risk of infection. The intracystic injection of bleomycin stopped the punctures of the reservoir.

Improved reservoir placement conditions (intraoperative guidance) and routine injection of bleomycin would likely reduce the rate of postoperative insipid diabetes and infectious complications related to punctures close to the reservoir.

Conflict of Interest

All the authors do not have any possible conflicts of interest.

References

- [1] Al Shail E, Al-Shenkiti A, Alotaibi MT, Siddiqui K, Al-Kofide A. Excision of pediatric craniopharyngioma: pattern of recurrence in 35 patients at a tertiary care hospital in Saudi Arabia. *Childs Nerv Syst.* 2019; doi: 10.1007/s00381-019-04349-z.
- [2] Azzoug S, Kabour S, Chentli F. Etude du diagnostic différentiel entre le prolactinome et le craniopharyngiome chez l'enfant. *Journal de Neurochirurgie.* 2014; 20: 21-26.
- [3] Bouaziz M, Belhouchet AA, Chaouchi I. Résultat du traitement d'un craniopharyngiome kystique par de la Bléomycine. *Journal de Neurochirurgie,* 2010; 12: 29-35.
- [4] Deghima s., Zellagui h., Chentli f, Augmentation de volume des craniopharyngiomes sous estrogènes et/ou hormone de croissance rôle des récepteurs hormonaux ou simple coïncidence? *Journal de Neurochirurgie.* 2013; 17: 5-10.
- [5] Fang Y, Cai BW, Zhang H, Liu W, Wu B, Xu JG, You C. Bléomycine intrakystique pour les enfants atteints de craniopharyngiomes kystiques. *Groupe de Revue Principal-Childhood Cancer Group,* 2013.
- [6] Grob1 S, Mirsky DM, Donson AM, Dahl N, Foreman NK, Hoffman LM, Hankinson TC, Levy JMM. Targeting IL-6 Is a Potential Treatment for Primary Cystic Craniopharyngioma. *Frontiers in Oncology.* 2019; 9 (791): 1-6.
- [7] Haddadi Y, Benbouali AS, Ghoul RB, Guesmi A, Debbabi M, Nebbal M. La curiethérapie des craniopharyngiomes kystiques expérience de l'hôpital central de l'armée. *Journal de Neurochirurgie.* 2018; 27: 20-25.
- [8] Lagha N, Benbouzid T, Tabbouche M, Bouyoucef S. Irradiation interstitielle par radio-isotopes des craniopharyngiomes kystiques. *Journal de Neurochirurgie.* 2011; 13: 19-23.
- [9] Lagha N, Morsli H, Tabouche M, Bouyoucef S, Benbouzid T. Traitement des craniopharyngiomes kystiques par radio isotopes résultats à long terme. *Journal de Neurochirurgie.* 2015; 21: 26-32.
- [10] Miyagishima T, Tosaka M, Yamaguchi R, Nagaki T, Ishii N, Kojima T, Yoshimoto Y. Extended endoscopic endonasal résection of craniopharyngioma using intraoperative visual evoked potential monitoring: technical note. *Acta Neurochir.* 2019; doi: 10.1007/s00701-019-04028-7.
- [11] Park HJ, Dho YS, Kim JH, Kim JW, Park CK, Kim YH. Recurrence rate and prognostic factors for the adult craniopharyngiomas in long-term follow-up. *World Neurosurg.* 2019; doi: 10.1016/j.wneu.2019.08.209.
- [12] Puget S, Beccaria K, Alapetite C, Kariyawasam D, Polak M, Zenaty D, Calmon R, Sainte-Rose C. Les craniopharyngiomes de l'enfant: stratégie de prise en charge. *MCED,* 2017; 86: 12-15.
- [13] Thiam AB, Ndoye N, Sylla N, Ba MC, Badiane SB. Le craniopharyngiome à propos de 11 cas. *Journal de Neurochirurgie.* 2013; 17: 20-29.
- [14] Toussaint L, Indelicato DJ, Muren LP, Li Z, Lassen-Ramshad Y, Kirby K, Pedro C, Mikkelsen R, Di Pinto M, Høyer M, Stokkevåg CH. Temporal lobe sparing radiotherapy with photons or protons for cognitive function preservation in paediatric craniopharyngioma. *Radiother Oncol.* 2019; doi: 10.1016/j.radonc.2019.08.002.
- [15] Xu SS, Wang LM, Zhao LH, He ZL, Gong LP, Lu DH, Teng LH. Implication of BRAF V600E and CTNNB1 gene mutations in the pathological classification of craniopharyngioma. *Zhonghua Bing Li Xue Za Zhi.* 2019; 48 (9): 682-687.
- [16] Zabsonré DS, Dabilgou AA, Dao A, Haro Y, Bako Y, Bambara B, Kabré A. Aspects épidémiologiques et évolutifs des tumeurs cérébrales au centre hospitalier universitaire. Yalgado Ouédraogo de Ouagadougou. *Burkina Médical.* 2016; 20 (01): 25-32.
- [17] Zeeshan Q, Hernandez JPC, Yoh NT, Sekhar LN. Complete Microsurgical Resection of Large Retrochiasmatic Hypothalamic Craniopharyngioma by Transpetrosal Approach: 2-Dimensional Operative video. *Operative Neurosurgery DOI:* 10.1093/ons/ozp250.